

Primary localized AA type amyloidosis of the renal pelvis, ureter and bladder

Li-Xin Shi¹, Gang Li², Lei Zhang³,
Bing Cong⁴, Xu Zhang⁵

ABSTRACT

We report an unusual variant, amyloid AA, of an already unusual condition, primary localized amyloidosis of the renal pelvis. Our patient is a 68-year-old man with a space-occupying lesion in left renal pelvis found by CT. He was suspected of having malignancy before ureteroscopy. Specimens were taken from the lesion site and pathological result was amyloidosis. No treatment has been given to him for the primary pelvic amyloidosis. New lesions were found in the bladder 10 months later and in the left ureter 21 months later, respectively. It is the first case of primary renal pelvic AA type amyloidosis in which the patient has been monitored for the progress of lesions in renal pelvis, ureter and bladder.

KEY WORDS: Amyloidosis, Kidney pelvis, Ureter, Bladder.

Pak J Med Sci April - June 2012 Vol. 28 No. 3 530-532

How to cite this article:

Shi LX, Li G, Zhang L, Cong B, Zhang X. Primary localized AA type amyloidosis of the renal pelvis, ureter and bladder. Pak J Med Sci 2012;28(3):530-532

INTRODUCTION

Amyloidosis is a group of diseases characterized by the extracellular deposition of the eosinophilic fibrillar protein in various tissues and organs. In the primary amyloidosis (AL), the amyloid deposit contains immunoglobulin light chains related proteins, usually occurs in conjunction with a plasma cell dyscrasia. In the secondary amyloidosis (AA), the amyloid comprises serum protein A produced

by the liver in response to cytokines from chronically inflamed tissues, which may result from diseases such as rheumatoid arthritis or tuberculosis. Hereditary amyloidosis (ATTR) comprises a heterogeneous group of conditions with distinctive patterns of organ involvement and familial clustering. Amyloidosis can also be classified as systemic (involving multiple organs, progressive and usually fatal) or localized (involving a single organ, does not progress and is rarely fatal).

Primary localized amyloidosis of urinary tract is rare, especially of the renal pelvis. With the clinical and radiographic presentation, it can closely resemble malignancy. It is extremely difficult to diagnose this condition preoperatively. We report the first case of primary renal pelvic amyloidosis in which the patient has been monitored for the progress in renal pelvis, ureter and bladder.

CASE REPORT

A 68-year-old man was admitted in October 2008 because of a space-occupying lesion in left renal pelvis found by CT (Fig.1). He had no complaint of gross hematuria or flank pain. The patient has received partial nephrectomy for angiomyolipoma of the right kidney in July 2007. His past medical

1. Li-Xin Shi,
2. Gang Li,
Institute of Organ Transplant of Chinese PLA,
309 Hospital of PLA, Beijing, 100091, China.
3. Lei Zhang,
4. Bing Cong,
5. Xu Zhang,
- 1,3-5: Department of Urology,
Chinese PLA General Hospital, Beijing, 100853, China.

Correspondence:

Gang Li, MD,
Institute of Organ Transplant of Chinese PLA,
309 Hospital of PLA, Jia No.17 Heishanhu Road,
Haidian District, Beijing, P.R.China, 100091.
E-mail: ligang@sina.com

- * Received for Publication: June 5, 2011
- * 1st Revision Received: July 11, 2011
- * 2nd Revision Received: February 29, 2012
- * Final Revision Accepted: March 5, 2012

history included high blood pressure, coronary heart disease, abnormal glucose tolerance and partial nephrectomy for right kidney angiomyolipoma in 2007. The physical examination was unremarkable. His full blood count and blood chemistry for renal function and liver function were within normal limits. Urinalysis showed numerous red blood cells per high power field.

Excretory urography showed an irregular filling defect in the upper pole calyx. CT revealed a nearly round nodule (13×11mm) with uniform density of connective tissue in the upper pole calyx and pelvis. This nodule showed slight and persist enhancement in renal cortical phase and parenchyma phase. In MRI, the lesion exhibited slight low signal intensity on T1- or T2-weighted images. Urine cytology did not reveal any atypical cells.

The patient was suspected of having malignancy. Ureteroscopy demonstrated clusters of pink, cauliflower-like neoplasm in pelvis and upper calyx (Fig.2a). Specimens were taken from the lesion site and pathological result was amyloidosis (Fig.2c). Additional investigation excluded systemic amyloidosis and amyloidosis secondary to rheumatic conditions, infections and malignancies. No treatment has been given to him for the primary pelvic amyloidosis.

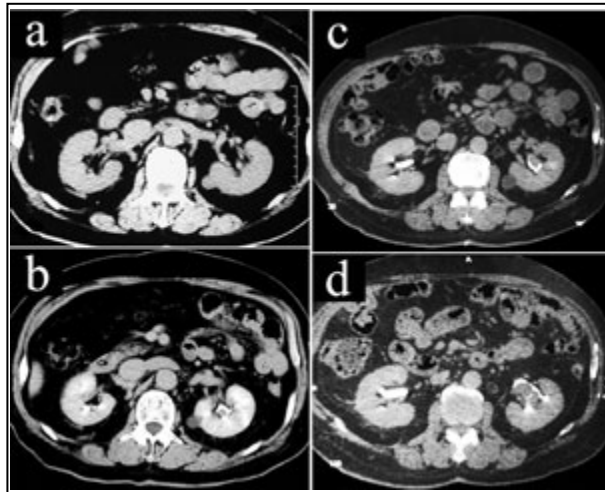


Fig.1: The plain and enhanced CT scanning showed the development of the lesion in left renal pelvis.

- (a) No lesion in left renal pelvis on Oct 25 2007 (plain scanning).
- (b) The lesion in left renal pelvis on Sep 27 2008 (delayed phase).
- (c) The lesion in left renal pelvis on Aug 13 2009 (delayed phase).
- (d) The lesion in left renal pelvis and left hydronephrosis caused by left ureteral lesion on Jul 8 2010 (delayed phase).

Ten months later, he was readmitted with bladder neoplasm. The left pelvic lesion increased to 20×15×14mm based on CT data. Cystoscopy demonstrated a papillary neoplasm (10×10mm) on the posterior wall. A transurethral biopsy of the bladder lesion was done, and the diagnosis of bladder amyloidosis was confirmed.

A CT scan 11 months after the second discharge revealed a neoplasm in the middle-lower part of the left ureter with left hydronephrosis. CT also showed enlarged lesions in left pelvis (30×40×25mm) and bladder. Cystoscopy demonstrated a cauliflower lesion on the left trigone (10×10mm) and another on the right posterior lateral wall (10×15mm) (Fig.2b). The patient received transurethral resection of these lesions but refused operation for ureter. Neither bladder irrigation treatment nor oral medication has been refused.

The specimens from the renal pelvis and bladder showed loss of congophilic staining when treated

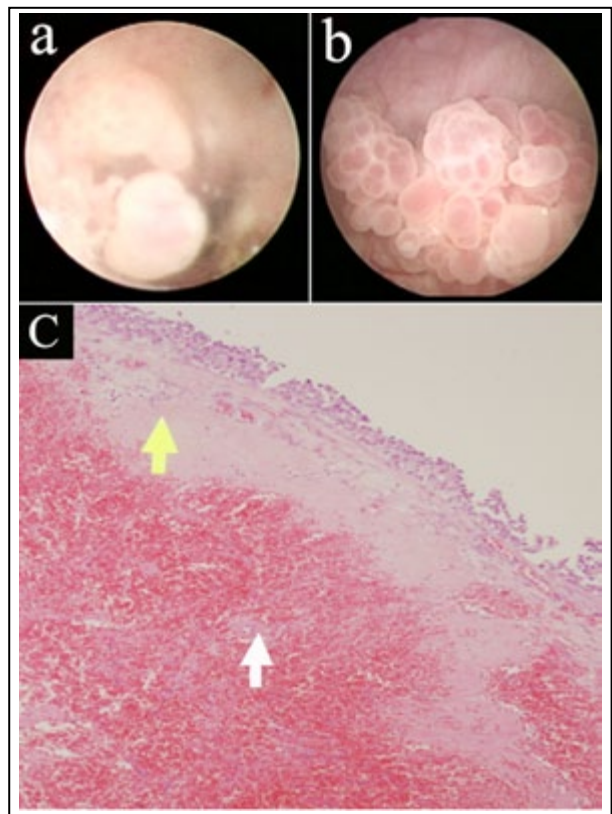


Fig.2: Photographs and microphoto of the lesions.

- (a) Clusters of pink, cauliflower-like neoplasm in pelvis and upper calyx.
- (b) Cauliflower lesions in bladder.
- (c) Amyloid deposition in the renal pelvic lamina propria (yellow arrow) and the wall of blood vessel (white arrow); HE staining (×40).

with potassium permanganate, consistent with AA amyloid.

DISCUSSION

Primary localized amyloidosis of urinary tract is a rare condition. A literature research in both PubMed and Chinese Medical Current Contents (CMCC) using the words "amyloido/amyloidosis + pelvis/ureter/bladder" revealed 24, 68 and 210 cases of primary localized amyloidosis of renal pelvis, ureter and bladder, respectively. Including the first case described in 1927¹, review of the 24 cases of primary localized amyloidosis of renal pelvis showed a peak incidence at between 50 to 70 years of age with a slight male predominance ratio of about 1.18 to 1 and slight right predominance ratio of 1.4 to 1.

The most important pitfalls among its investigation arise due to the overlapping clinical and radiological similarities with those observed in upper urinary tract neoplasm, thus providing unnecessary radical surgical treatment. Among the 24 cases described to date, more than 90% of the patients presented clinically with hematuria. Radiology showed a filling defect suspicious of neoplasm. The surgical treatment was radical nephroureterectomy or nephrectomy in more than 80% of the patients.

AL amyloid is the material found in most cases of primary localized amyloidosis of the urinary tract. Primary localized AA type amyloidosis of the urinary tract is rare, with only three cases have been reported.²⁻⁴ AA amyloid has been described in association with systemic inflammatory and infectious conditions. However, when specifically questioned and investigated, the patient had no evidence of rheumatoid arthritis, Crohn's disease, ankylosing spondylitis, familial Mediterranean fever, tuberculosis or chronic urinary tract infections. Thus, our case represents an unusual variant, amyloid AA, of an already unusual condition, primary localized amyloidosis of the urinary tract.

Various methods have been employed in the treatment of primary localized amyloidosis of urinary tract. For bladder lesions electrocautery or laser fulguration, transurethral resection and partial or total cystectomy have all been employed based on the size and number of lesions. Intravesical Dimethyl sulfoxide (DMSO)^{5,6}, oral cepharanthine⁷ and colchicines⁸ have also been reported in rare cases with limited success. For the upper urinary lesions, surgical intervention is usually unavoidable, because it is very difficult to distinguish this disease from ureteral malignancy.

Fushimi reported the first case with primary amyloidosis of ureter successfully treated by oral administration of prednisolone.⁹

However, there is no reported case of any successful medical interventions in the treatment of primary localized amyloidosis of renal pelvis. Borza reported the first patient of primary renal pelvic amyloidosis in which no therapeutic intervention has been taken and the patients have been merely monitored with imaging.¹⁰ His patients did not develop any additional lesions nor had recurrence of their symptoms during a 15-month follow-up.

In our study, the patient did not receive any surgical treatment or oral medication for pelvic amyloidosis too. However, bladder amyloidosis and left ureter amyloidosis with moderate left hydronephrosis were found 10 months and 21 months later, respectively. The left pelvic lesion has also increased from 13×11×10mm (2008 Sep 27) to 20×15×14mm (2009 Aug 13) to 30×40×25mm (2010 Jul 8) (Fig.1). As such, it behaved like a low-grade noninvasive and nonmetastatic but multiple destructive and recurrent malignancy. The patient is still in follow-up.

REFERENCES

1. Chisholm GD, Cooter NBE, Dawson JM. Primary amyloidosis of the renal pelvis. *Br Med J* 1967;1:736-738.
2. Akram CM, Al-Marhoon MS, Mathew J, Grant CS, Rao TV. Primary localized AA type amyloidosis of urinary bladder: case report of rare cause of episodic painless hematuria. *Urology* 2006;68:1343.e15- e17.
3. Boorjian S, Choi BB, Loo MH, Kim P, Sandhu J. A rare case of painless gross hematuria: primary localized AA-type amyloidosis of the urinary bladder. *Urology* 2002;59:137.
4. Kono M, Komatsu K, Nagasaka Y, Namiki M. Primary AA type amyloidosis of the urinary bladder: a case report. *Hinyokika Kyo* 2000;46:197-199.
5. Malek RS, Wahner-Roedler DL, Gertz MA, Kyle RA. Primary localized amyloidosis of the bladder: experience with dimethyl sulfoxide therapy. *J Urol* 2002;168:1018-1020.
6. Tokunaka S, Osanai H, Morikawa M, Yachiku S. Experience with dimethyl sulfoxide treatment for primary localized amyloidosis of the bladder. *J Urol* 1986;135:580-582.
7. Nishiyama T, Gejyo F, Katayama Y, Takeda M, Takeda M, Sato S. Primary localized amyloidosis of the bladder: a case of AL (lambda) amyloid protein and combination therapy using dimethyl sulfoxide and cepharanthine. *Urol Int* 1992;48:228-231.
8. Livingstone RR, Sarembock LA, Barnes RD, Folb PI. Colchicine therapy in primary amyloidosis of the bladder: a case report. *J Urol* 1989;142:1570-1571.
9. Fushimi T, Takei Y, Touma T, Kudoh S, Yamamoto K, Hoshii Y. Bilateral localized amyloidosis of the ureters: clinicopathology and therapeutic approaches in two cases. *Amyloid* 2004;11:260-264.
10. Borza T, Shah RB, Faerber GJ, Wolf JS Jr. Localized Amyloidosis of the Upper Urinary Tract: A Case Series of Three Patients Managed with Reconstructive Surgery or Surveillance. *J Endourol* 2010;24:641-644.