

Robotic Surgery in Gynecology Practice: Current Approaches

Mustafa Kara

ABSTRACT

Laparoscopic surgery has been widely used in gynecology practice for more than 20 years. Despite the advent of laparoscopy led to advances, it has not been widely used in gynecology because of some disadvantages, including two-dimensional imaging, unstable camera platform, limited mobility of laparoscopic instruments. The aim of this study was to evaluate the advantage and disadvantages of the robotic surgery, especially the da Vinci system. Robotic surgery utilization in gynecology field has been studied in many trials. The literature was searched, advantages and disadvantages of robotic surgery were evaluated. This paper showed that previous studies which have been done suggest robotic surgery can be used in gynecologic interventions. Two-dimensional imaging is replaced with three dimensional technique in the da Vinci robot with increased perception and magnification. Moreover, tremor and motion scaling which complicate the operation are not seen in the robotic surgery and the surgical procedures that are typically difficult can be done easier than laparoscopy. However, the price and the loss of tactual feeling are accepted as big disadvantages of robotic surgeries. This manuscript will highlight the science behind the robotic surgery, recent advances in minimally invasive surgery, the most recent clinical trial results and important issues we need to consider prior to implementation of the robot in Turkey.

KEY WORDS: Robotic surgery, da Vinci robot, Gynecology, Laparoscopy, Minimally invasive surgery.

Pak J Med Sci January - March 2012 Vol. 28 No. 1 238-241

How to cite this article:

Kara M. Robotic Surgery in Gynecology Practice:Current Approaches. Pak J Med Sci 2012;28(1):238-241

-
1. Dr. Mustafa Kara,
Assistant Professor,
Department of Obstetrics and Gynecology,
Bozok University Medical Faculty,
Yozgat, Turkey.

Correspondence:

Dr. Mustafa Kara,
Assistant Professor,
Department of Obstetrics and Gynecology,
Bozok University Medical Faculty,
Yozgat, Turkey.
Address: Bozok University Medical Faculty,
Adnan Menderes Boulevard No. 190,
66200 Yozgat/ Turkey.
E-mail: mustafa.kara@bozok.edu.tr
opdrmustafakara@hotmail.com

- * Received for Publication: August 19, 2011
- * 1st Revision Received: August 27, 2011
- * 2nd Revision Received: September 29, 2011
- * 3rd Revision Received: December 20, 2011
- * Accepted for Publication: December 21, 2011

INTRODUCTION

The da Vinci robotic system (Intuitive Surgical Systems, Inc., Sunnyvale, CA) is the most important advancement in the minimally invasive surgery of last decade. It was introduced by Intuitive Surgical Systems in 1999 and was accepted by Food and Drug Administration (FDA) in April 2005 for gynecologic procedures. This technology is being adopted rapidly to standard laparoscopic techniques such as hysterectomy, myomectomy, sacral colpopexy, lymph node dissection operations performed in the U.S. Despite this system is being used widely in the United States of America it is not performed for most gynecologic interventions in all over the world, especially in Asia.

The da Vinci Surgical System: The da Vinci surgical instrument contains the surgical console, robotic

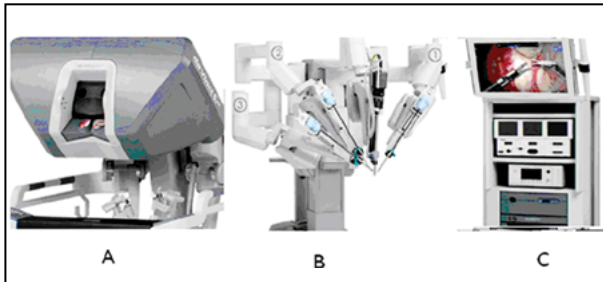


Fig.1: The da Vinci robot. (A) The surgeon console (B) Robotic cart (C) Endoscopic stack.

cart, and the endoscopic stack (Fig.1). The surgical console consists of binocular vision system, instrument controllers, and foot pedals. The vision system consists of two micro cameras and two optic cables transforming the two-dimensional imaging to the binocular imaging. The instrument controllers are commanded by thumb and index finger of each hand. The surgeon is seated in an ergonomic position and moving these two fingers lead to the attached devices. There are five foot pedals. These pedals are used to adjust the instruments, camera focus, bipolar and monopolar cautery.

The robotic cart contains four mechanical arms and these arms are joined to the surgical console via a channel. Each arm has three or four articulating parts providing the movements easily. The central arm contains the optic system. The weight of the cart is nearly 500kg and it can be operated easily on a wheel base. The endoscopic stack contains monitor, light source, and CO₂ insufflator.

Firstly, the laparoscopic ports are placed and docking the robotic arms, the surgeon manipulates attached instruments. Two-dimensional imaging is replaced with three dimensional in the da Vinci robot with increased perception and magnification. Moreover, tremor and motion scaling which complicate the operation are not seen in the robotic surgery and the surgical procedures that are typically difficult can be done easier than laparoscopy.^{1,2} Finer and more dexterous movements due to wrist like motion of the robotic arm allow to enable operations which is difficult for traditional laparoscopy with robot such as intracorporeal suturing and knot tying. The bedside assistant can suction, grasp, and pass suture through an accessory laparoscopic port, as well as manipulate the uterus. The surgeon is seated and more comfortable in robotic technology than a standing and holding two instruments laparoscopic surgeon. Consequently, the limiting factors such as fatigue and frustration are less important for robotic surgeon. In addition potential for telesurgery shorter hospital stay, minimal pain,

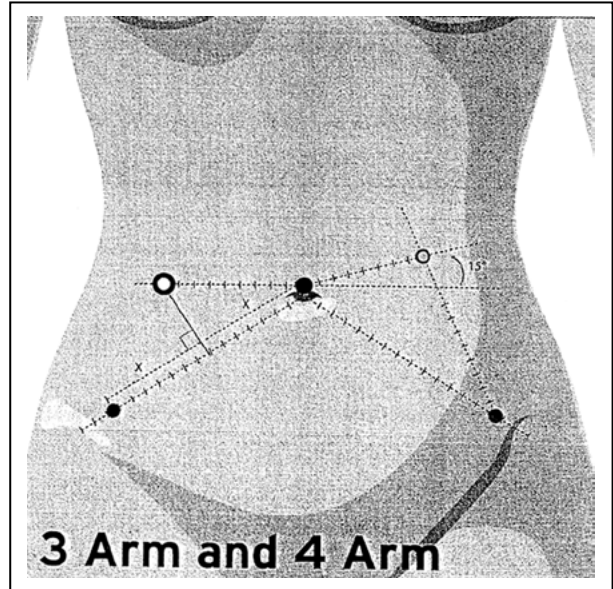


Fig.2: Robotic port placement for benign gynecologic conditions.

quick recovery, and decreased blood loss are other advantageous of robotic surgery.^{3,4} The loss of tactual feeling is the major problem of the surgeons using da Vinci robot. The lack of tactile feeling and high cost are limitations of this system.

Port Placement: The recommendations about port placement by the Intuitive Surgical Company which developed and marketed the da Vinci surgical robot as follows: da Vinci endoscope port (12mm) are placed directly above the umbilicus. Right da Vinci instrument (8mm) is placed on the patient's right side, 2-3 cm from the anterior superior iliac spine, along a line to the umbilicus. Left da Vinci instrument port (8mm) is placed on the patient's left side, offset superiorly on a 15 degree angle from the camera port, 8cm from the endoscope port and at least 8cm from the 4th arm port. This port not used with 3 arm system. The fourth arm da Vinci

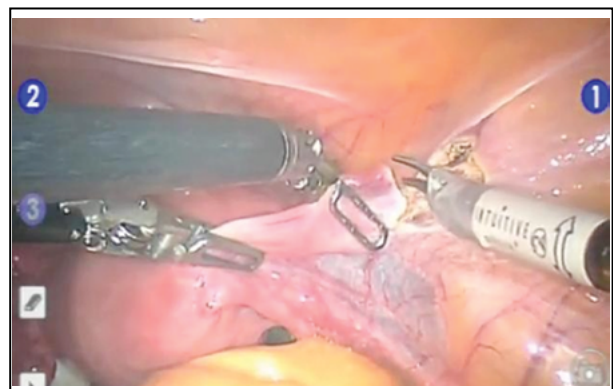


Fig.3: Robotic hysterectomy.

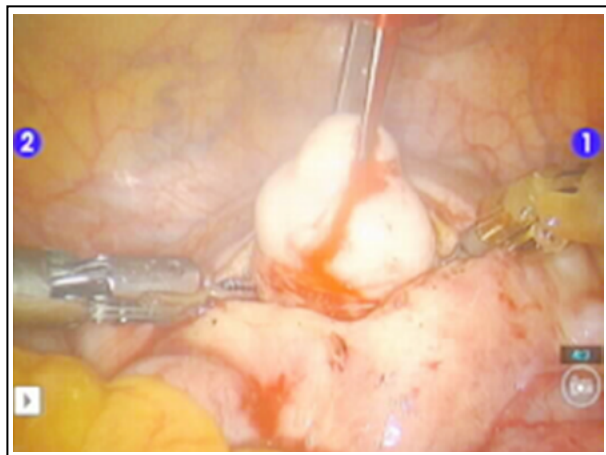


Fig.4: Robotic myomectomy.

port (8mm) is placed on the patient's left side, 2-3 cm from the anterior superior iliac spine, along a line to the umbilicus. This is the port location for the left instrument arm when using a 3 arm system (Fig.2).

Gynecologic Robotic Procedures: There is limited data about the usage of the robotic surgery in gynecology field. Literature consists of descriptive retrospective case series. Large, randomized, prospective studies to evaluate the outcomes of the surgeries and costs are needed. Information is insufficient to suggest that robotic-assisted procedures might be superior than other techniques. Mostly heterogenous, small retrospective studies have shown safety and feasibility for tubal reanastomosis, hysterectomy, prolapse, myomas up to 2000gm, adenomyosis, lymph node dissection, ovarian remnant syndrome, endometriosis, adhesion, and pelvic pain. Future prospective studies are required.⁵⁻⁸

The robotic learning curve for a single surgeon was found to be steep in a study reported by Bell et al.⁹ Nezhat et al reported that robotic-assisted surgery was found to be effective for endoscopic surgery. Learning curve for suturing is faster in this procedure and the quality of the image is better.³ The first 20 cases were more important than other cases because the surgeons acquired their surgical skills in these first cases. Lenihan et al reported that the learning curve for experienced surgeons was shorter than beginners it was defined as 50 cases.⁴ Guru and co-workers compared the robotic and laparoscopic surgery in their study. Although the robotic procedures were more time consuming the suturing process were performed in a shorter time in with robot than laparoscopy. Suturing with laparoscopy was defined difficult and impossible

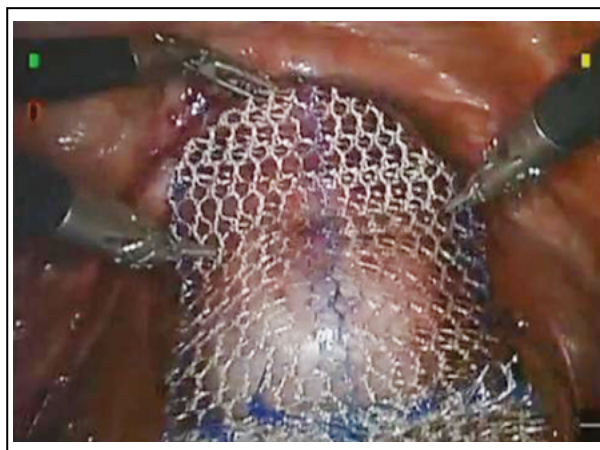


Fig.5: Robotic sacrocolpopexy.

in 73% and 9% of the participants, respectively in the same study.¹⁰ Robotic surgery was found to be successful for hysterectomy as much as standard laparoscopic hysterectomy (Fig.3). It contains technologic convenience such as remote telesurgery, and easiness of teaching endoscopic surgery.^{11,12} Boggess et al reported that robotically assisted total hysterectomy for benign gynecologic indications is capable and requires low morbidity and a short hospital stay. Their study suggests that robotic approach is easier than conventional procedures and minimally invasive for high-risk patients.¹³ Advincula et al¹⁴ compared with robot-assisted laparoscopy and traditional laparotomy and analyzed the cost of these two operations. The blood loss and hospital stay were found to be less in robotic group than laparoscopic group. However, the cost of the operation was higher in robotic myomectomy group than the other one. Bedient et al¹⁵ assessed the success of robot-assisted and laparoscopic myomectomy. Short-term surgical outcomes were similar according to their data. Nezhat et al¹⁶ compared with robot-assisted and standard laparoscopic myomectomy in a retrospective matched control study (Fig.4). They reported the same short term outcomes in these two groups.

Robotic surgery contains various benefits for pelvic floor reconstructive surgery (Fig.5). The usage of robotic surgery in urogynecologic surgery will increase and this technology is an enabler in laparoscopic surgery, especially in microsurgical and suture-intensive operations.^{17,18}

CONCLUSION

Advanced laparoscopic surgery is a milestone at the beginning of minimally invasive pelvic surgery.

The limited mobility of the laparoscopic instruments, two-dimensional imaging, unstable camera, long learning curve, and a poor ergonomic position are the disadvantages of the laparoscopy. These difficulties caused to the invention of the da Vinci robot. Robotic surgery is a new milestone. The da Vinci robot has a lot of technical advantages including easy manipulation, high image quality, ease of use. Furthermore, it is convenient for inexperienced surgeons and the learning curve is short. However, high cost associated with this technology, necessity of extra time to set up and docking (variable team effort), lack of tactile feedback and sensation, inability to reposition the patient (Trendelenburg position), and bulkiness of the current system (uterine manipulation) are main disadvantages. Despite these limitations much attention should be paid to the promise of the robotic surgery.

ACKNOWLEDGEMENTS

I am grateful to Assoc. Prof. Dr. Ceana Nezhat who works at Endoscopy Laser Institute of Atlanta for his kind assistance to improve my professional surgical training.

REFERENCES

- Holloway RW, Patel SD, Ahmad S. Robotic surgery in gynecology. *Scand J Surg* 2009;98(2):96-109.
- Kim YT, Kim SW, Yung YW. Robotic surgery in gynecologic field. *Yonsei Med J* 2008;49(6):886-90.
- Nezhat C, Lavie O, Lemyre M, Unal E, Nezhat CE, Nezhat F. Robot-assisted laparoscopic surgery in gynecology: scientific dream or reality? *Fertil Steril* 2009;91(6):2620-2.
- Lenihan JP, Kovanda C, Seshadri-Kreaden U. What is the learning curve for robotic assisted gynecologic surgery? *J Minim Invasive Gynecol* 2008;15(5):589-94.
- Palep JH. Robotic assisted minimally invasive surgery. *J Minim Access Surg* 2009;5(1):1-7.
- Advincula AP, Song A. Role of robotic surgery in gynecology. *Curr Opin Obstet Gynecol* 2007;19:331-6.
- Visco AG, Advincula AP. Robotic gynecologic surgery. *Obstet Gynecol* 2008;112(6):1369-84.
- Schreuder HWR, Verheijen RHM. Robotic surgery. *BJOG* 2009;116:198-213.
- Bell MC, Torgerson JL, Kreaden U. The first 100 da Vinci hysterectomies: an analysis of the learning curve for a single surgeon. *S D Med* 2009;62(3):91-5.
- Guru KA, Kuvshinoff BW, Pavlov-Shapiro S, Bienko MB, Aftab MN, Brady WE et al. Impact of robotics and laparoscopy on surgical skills: A comparative study. *J Am Coll Surg* 2007;204:96-101.
- Nezhat C, Lavie O, Lemyre M, Gemer O, Bhagan L, Nezhat C. Laparoscopic hysterectomy with and without a robot: Stanford experience. *JLS* 2009;13:125-8.
- Shashoua AR, Gill D, Locher SR. Robotic-assisted total laparoscopic hysterectomy versus conventional total laparoscopic hysterectomy. *JLS* 2009;13(3):364-9.
- Bogges JF, Gehrig PA, Cantrell L, Shafer A, Mendivil A, Rossi E, et al. Perioperative outcomes of robotically assisted hysterectomy for benign cases with complex pathology. *Obstet Gynecol* 2009;114(3):585-93.
- Advincula AP, Xu X, Goudeau S, Ransom SB. Robot-assisted total laparoscopic myomectomy: a comparison of short-term surgical outcomes and immediate costs. *J Minim Invasive Gynecol* 2007;14(6):698-705.
- Bedient CE, Magrina JF, Noble BN, Kho RM. Comparison of robotic and laparoscopic myomectomy. *Am J Obstet Gynecol* 2009;201(6): 566.e1-5. Epub 2009 Aug 15.
- Nezhat C, Lavie O, Hsu S, Watson J, Barnett O, Lemyre M. Robotic-assisted laparoscopic myomectomy compared with standard laparoscopic myomectomy: a retrospective matched control study. *Fertil Steril* 2009;91(2):556-9.
- Moy ML, Byun SY. Role of robotic surgery in urogynecologic surgery. *Curr Opin Urol* 2010;20(1):70-4.
- Ross JW, Preston M. Updated on laparoscopic, robotic, and minimally invasive vaginal surgery for pelvic floor repair. *Minerva Ginecol* 2009;61(3):173-86.