

Foreign body nose in children presenting at a tertiary care teaching hospital in Pakistan

Muhammad Hafeez¹, Zakirullah², Inayatullah³

ABSTRACT

Objectives: To determine the patient management factors and patient outcomes in pediatric patients of foreign bodies in nose.

Methodology: This descriptive study was performed in ENT Department, Khyber Teaching Hospital, Peshawar from February, 2006 to January, 2007. Two hundred fifty seven cases of foreign bodies in nose in patients upto 12 years of age were included. Personal data, clinical features, investigations, management details and complications were recorded on a pre-designed proforma. In younger non cooperative cases foreign bodies were removed under general anesthesia, while in cooperative children it was removed without anesthesia by using suction, use of forceps and foreign body hook.

Results: Among 257 cases of foreign bodies in nose 48.46% were between 4 to 8 years, with male preponderance i.e. 63%. Unilateral and bilateral presentations were seen in 95% and 5% cases respectively. Most common foreign body types were plastic beads, pearls, pieces of sponge and small round objects. There were two cases of alkaline battery lodged in the nose. General anesthesia had high success rate.

Conclusion: Round shape foreign bodies and younger children are associated with poor outcome with removal attempts made under direct visualization. These cases should be referred directly to otolaryngologists for removal under general anesthesia.

KEY WORDS: Nose, Foreign body, Pediatric, General anesthesia.

Pak J Med Sci January - March 2011 Vol. 27 No. 1 124-127

How to cite this article:

Hafeez M, Zakirullah, Inayatullah. Foreign body nose in children presenting at a tertiary care teaching hospital in Pakistan. Pak J Med Sci 2011;27(1):124-127

INTRODUCTION

The removal of foreign bodies in children is very common in the otolaryngologists daily routine.¹

1. Dr. Muhammad Hafeez, MBBS, FCPS,
2. Dr. Zakirullah, MBBS, DLO, MCPS, FCPS,
3. Dr. Inayatullah, MBBS, MCPS, FCPS,
- 1-3: Department of ENT,
Khyber Teaching Hospital,
Peshawar, Pakistan.

Correspondence:

Dr. Muhammad Hafeez,
Consultant ENT,
Khyber Teaching Hospital,
Peshawar, Pakistan.
E-mail: drmohammadhafeez@yahoo.com
gohar28@hotmail.com

- * Received for Publication: March 2, 2010
- * Revision Received: October 11, 2010
- * Revision Accepted: October 13, 2010

Nasal foreign bodies are commonly encountered in emergency departments. Although more frequently seen in the pediatric setting, they can also affects adults, especially those with mental retardation or psychiatric illness.² Children's interests in exploring their bodies make them more prone to lodging foreign bodies in their nasal cavities. In addition, they may also insert foreign bodies to relieve pre-existing nasal mucosal irritation or epistaxis. As benign as nasal foreign body may seem, it harbors the potential for morbidity and even mortality if the object is dislodged into the airway.^{3,4}

Foreign bodies can be classified as either inorganic or organic. Inorganic materials are typically plastic or a metal.⁵ Common examples include beads, button, stones, paper and small parts from toys. These materials are often asymptomatic and may be discovered incidentally. Organic foreign bodies,

including food, rubber, wood, sponge, and metallic batteries, tend to be more irritating to the nasal mucosa and thus may produce earlier symptoms.⁶

The most common locations for nasal foreign bodies to lodge are just anterior to the middle turbinate or below the inferior turbinate.⁷ Unilateral foreign bodies affect the right side about twice as often compared to the left. This may be due to preference of right handed individuals to insert objects in their right nares.⁸

Button batteries inserted into the nose can cause septal perforation. Unsuccessful efforts to remove the foreign body may cause local injury, pain and bleeding, making subsequent attempts at removal more difficult.^{9,10}

This is an important study to categorize nasal foreign bodies characteristics, frequency in different paediatric age groups, management techniques and to analyze patient outcomes based on these factors. This would help to determine the most appropriate management for paediatric patient with foreign body nose when they present to the emergency department or outpatient department.

METHODOLOGY

This descriptive study was performed in ENT Department Khyber Teaching Hospital, Peshawar over a period of one year from February, 2006 to January, 2007. Two hundred fifty seven cases of foreign bodies in nose were included, upto 12 years of age.

Personal data, clinical features, investigations, surgical management details and complications were recorded on a pre-designed proforma. Mostly children presented in emergency or in out patient department along with their parents with complaints of foreign body in nose on the same day, or after 2-3 days, some older than 2-3 weeks. The various methods used for removal of foreign bodies were direct visualization and removal with forceps. Foreign body hook and use of suction. Those children who were not cooperative, or failure of foreign body removal due to deep impaction, or had previous unsuccessful attempts were prepared for removal under general anesthesia.

Table-I: Age Distribution (N=257)

Age group	No. of %	%	Male	Female
1-4 years	85	33.07%	54	31
4-8 years	125	48.46%	72	53
8-12 years	47	18.46%	36	11

RESULTS

In our case series the most common paediatric age group involved was 4-8 years (48.46%) as shown in Table-I. The sex distribution was 162 males and 95 females. The most common foreign body type was plastic beads, pearls while other type were sponge piece and paper piece, stones, vegetable seeds, rubber piece and button battery cells. Table-II.

The emergency department residents had encountered number of complications for removal of foreign bodies without general anesthesia which were bleeding, failure of foreign body removal, deeper displacement and pain. Table-III.

Figure-I shows foreign bodies removed without general anesthesia were 20.7% from one to four years, 49.9% under 4 to 8 years and 69.8% under 8-12 years of age groups, while under general anesthesia 96.6% from 1-4 years, 84.7% 4-8 years, 55.7% 8-12 years.

DISCUSSION

Despite the high frequency of foreign body insertion into the nose, there are very few studies on this problem in literature.¹⁻¹⁰ Success in removing a foreign body nose depends on a number of factors including the size, shape and texture of the foreign body, time duration of F.B, the cooperation of patient at the time of removal, the ability to visualize the F.B and surrounding structure, trauma to the nasal cavity due to insertion or attempted removals of the F.B, the equipment available for removal and skill of the doctor attempting the removal.²

In our study the most common age group was 4 to 8 years. 48.46%. This was comparable to a study done in Singapore 43.3%.¹¹ While in contrast study done in Lahore showed 71%² in same age group. In our case series foreign bodies were found in males

Table-II: Type of Foreign Bodies (N=257)

Types of foreign body	No.	%
Beads or pearls	137	53.3%
Paper	45	17.5%
Sponge piece	35	13.6%
Rubber piece	18	7%
Stones	12	4.6%
Seeds	5	1.94%
Button battery	5	1.94%

Table-III: Outcome of F.B removal in emergency without General Anaesthesia

Failure of foreign body removal	26%
Bleeding	28.8%
Injury to surrounding structures	13.2%
Posterior displacement and others	14.9%

63.84% and females 36.15%, which is comparable to study done in America in which males 52% and female 48%.

In our case series most common foreign body type were plastic beads and pearls. They were 53.3% while other type were paper piece 17.5%, sponge piece 13.6%, rubber piece 7%, stones 4.6%, seeds 1.94% and button batteries 1.94%.

We observed that children under four years showed lower success rate for foreign body removal without anesthesia (20.7%) than with general anesthesia (96.6%). Patients in this age group have smaller nasal cavities, tends to be some what less cooperative, potentially making FB removal more technically challenging. In the study of Shulze SL, over 95% of patients requiring FB removal under general anesthesia were under four years of age.¹²

Alkaline button batteries cause extensive liquefaction necrosis of surrounding tissues by leaking alkaline electrolytes solution causing septal perforation. In our series we had two cases of Alkaline button battery septal perforation.¹³

Removal techniques varied in emergency, primarily use is direct visualization with proper instrument for foreign body removal along with use of suction. According to our study spherical foreign bodies demonstrated the largest difference in success rates between direct visualization and removal under general anesthesia, with direct visualization in non cooperative patients having a much lower success rates which was also discussed in Davis and Bengner study.¹⁰

We observed that spherical Foreign bodies were associated with highest complication rate due to multiple attempts. In contrast, soft paper or plastic foreign bodies had high success rates of removal under direct visualization. The difference in outcome between these two foreign body classes is likely to be due to the difference in foreign body shape and texture. Spherical foreign bodies are difficult to grasp with nasal forcep, where as paper tissue may offer free edge to grasp easily. Those foreign bodies which did not completely occlude the nasal cavity may be

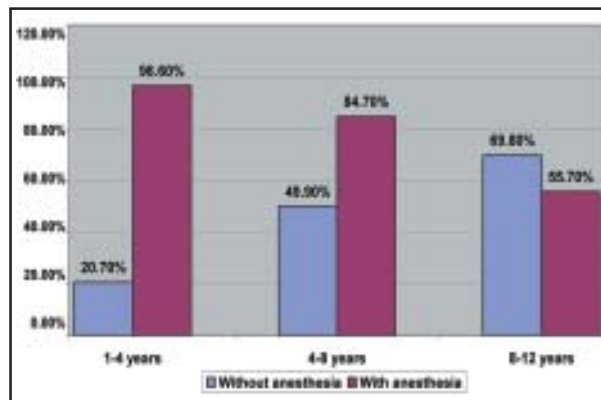


Fig-1: Age analysis according to the rate of successful removal in different age group of pediatric patients.

removed by right angle hook but are associated with number of complications.

Outcome of foreign body removal without anesthesia in our study were bleeding 28.8%, failure of foreign body removal 26.4%, injury to surrounding structures 13.2%, posterior displacement 14.9%.

Objects in the nose can cause damage to the nasal cavity and surrounding structures. They can produce local inflammation, which may result in a pressure necrosis. This in turn, can cause mucosal ulceration and erode into blood vessels producing epistaxis. The swelling can cause obstruction to sinus drainage and lead to secondary sinusitis. Organic foreign bodies tend to swell and are usually more symptomatic than inorganic foreign bodies.

Finally impacted and unrecognized foreign bodies can in time become coated with calcium, magnesium, phosphate or carbonate and become a rhinolith. Rhinoliths can remain undetected for years and only upon growth do they produce symptoms that lead to their discovery. Nasal Foreign bodies often fail to be recognized for longer periods of time because they usually produce fewer symptoms and are more difficult to visualize.

CONCLUSION

Foreign body nose in pediatric patients are commonly encountered in emergency department. In general, nasal foreign bodies can be safely removed by emergency department physician. However the goal of management should be to minimize complications which often occurs from repeated attempts of removal. In many situations direct visualization without anesthesia will allow for successful removal of foreign body, but in cases

shown to have low chances of successful removal and high risk of complication, removal of foreign body under general anesthesia should be first line of management.

ACKNOWLEDGMENT

Special thanks to Mr. Gohar Said (Composing Center) Near KTH, Peshawar for his secretarial help and assistance.

REFERENCES

1. Francois M, Hamrioui R, Narcy P. Nasal foreign bodies in children. *Eur Arch Otorhinolaryngol* 1998;255(3):132-134.
2. Botma M, Bader R, Kubba H. 'A parent's Kiss': Evaluating an unusual method for removing nasal foreign bodies in children. *J Laryngol Otol* 2000;114(8):598-600.
3. Mackle T, Conlon B. Foreign bodies of the nose and ears in children. Should these be managed in accident and emergency setting *Int J Pediatr Otorhinolaryngol* 2006;70:425-428.
4. Hon SK, Izam TM, Koay CB, Razi A. A prospective evaluation of foreign bodies presenting to the Ear, Nose and Throat clinic, University Hospital Kuala Lumpur, *Med J Malaysia* 2001;463-470.
5. A NGO, Kc Ng, Sim TP. Otolaryngeal foreign bodies in children presenting to emergency dept. *Singapore Med J* 2005;172-178.
6. Backlin SA. Positive-pressure technique for the removal of nasal foreign bodies in children. *Ann Emerg Med* 1995;25(4):554-555.
7. Baluyot ST. Foreign bodies in the nasal cavity. In: Paparella MM, Shumrick DA, eds. *Otolaryngology*. Vol 3. 2nd ed Philadelphia, PA: W.B Saunders, 1980: 2009-2016.
8. Chan TC, Ufberg J, Harrigan RA, Vilke GM. Nasal foreign body removal. *J Emerg Med* 2004;26(4):441-445.
9. Das SK. Aetiological evaluation of foreign bodies in the ear and nose. *J Laryngol Otol* 1984;98:989-991.
10. Davis P, Bengen J. Foreign bodies in the nose and ear: A review of technique for removal in emergency department. *J Accid Emerg Med* 2000;17:91-94.
11. Tong MC, Ying SY, van Hasselt CA. Nasal foreign bodies in children. *Int J Pediatr Otorhinolaryngol* 1996;35:207-211.
12. Schulze SL, Kerschner J, Beste D. Pediatric foreign bodies. A review of 698 cases. *Otolaryngol Head Neck Surg* 2002;127:73-78.
13. Hong D, Chu YF, Tong KM, Hsiao CJ. Button battery as a foreign body in the nasal cavities. *Int J Pediatr Otorhinolaryngol* 1987;14(1):15-19.

Electronic Submission of Articles

"PAKISTAN JOURNAL OF MEDICAL SCIENCES" now accepts electronic submission of articles via e-mail, attachment in MS Word format at any of the following addresses:

pjms@pjms.com.pk
pulse@pulsepakistan.com

Note: The figures should be sent in JPEG format to ensure good quality images.

(Arrangements are also being made to accept manuscripts through our website in due course of time)

Electronic submission saves time, postage costs and allows the manuscript to be handled in electronic form throughout the publication process.

Processing Charges: Effective January 1st, 2010 all manuscripts from Pakistan should be accompanied with a Cash or Bank Draft for Rs. 1,000/- (Non-refundable) in the name of Pakistan Journal of Medical Sciences. Add Rs. 250/- in case of cheque.)

For detailed instructions to authors visit our website

pjms.com.pk