APPENDICITIS AND *ENTEROBIUS VERMICULARIS*

Sarmast MH[1], Maraghi S[2], Elahi A[3] & Mostofi NE[4]

ABSTRACT

Objective: To evaluate the appendicitis due to *Enterobius vermicularis*.

Design: Appendices were removed and histopathological examination was carried out.

Setting: The samples were obtained from patients admitted in Imam khomeini hospital at Ahvaz city, capital of Khouzestan Province, Southwestern part of Iran.

Subjects: 1253 appendices were examined in order to elucidate possible relationship between the incidence of *Enterobius vermicularis* and the origin of inflammation.

Main outcome: Assesment of the appendicitis due to *Enterobius vermicularis*.

Results: Nine out of 1253 cases (0.7%) were infected with *Enterobius vermicularis*, including 5 female and 4 male at the age of 8-36 years. During the operation in two female cases, ovarian cysts were revealed at the same time.

Conclusion: Existence of *Enterobius vermicularis* in appendicitis can cause the symptom and even inflammation of appendicitis.

KEYWORDS: Appendix, *Enterobius vermicularis*, Worms, Appendicitis

Pak J Med Sci April-June 2005 Vol. 21 No. 2 202-5

INTRODUCTION

Enterobius vermicularis is the most common intestinal parasite of man with the widest geographical distribution specially in the primary care setting regardless of race, socioeconomic or culture circumstances[1]. Over 200 million persons are infected in the world. The male pinworm is about 2-5mm in length and the female reaches a length of 8-13mm. Upon ingestion of embryonated egg, first stage larva hatches in the duodenum. The liberated rhabditiform larva moult twice before reaching adolescence in the jejunum and upper ileum[2]. The adult worms inhabit the cecum and adjacent portion of the large and small intestine. The female worms when fully gravid, migrate down the intestinal tract to pass out of the anus and deposit their eggs. the clinical symptoms are due largely to the perianal. Perianal and vaginal irritation caused by the migration of the gravid female worm. Although the natural babitat of pinworm is in large intestine, but it can migrate as an erratic worm and localize in other organs[3]. In this study 9 cases of appendicitis due to *Enterobius vermicularis* were assessed.

1. Department of Surgery
2. Department of Mycoparasitology
3. Department of Surgery
4. Department of Pathology

1-4. Imam Khomeini Hospital,
School of Medicine,
Jundi-Shapour University of Medical Sciences,
Ahvaz, Iran

Correspondence:

Prof. S. Maraghi
Department of Mycoparasitology,
School of Medicine,
Jundi-Shapour University of Medical Sciences,
Ahvaz, Iran
E - Mail: maraghi_s@yahoo.com

* Received for publication: October 22, 2004

Accepted: November 30, 2004

MATERIALS AND METHODS

1253 removed appendices within 5 years (1995–1999) at the department of surgery, Imam Khomeini Hospital, Ahvaz, Iran were sent to the pathology lab in order to elucidate possible relationships between the incidence of *Enterobius vermicularis* and the origin of inflamation in the appendicitis. The samples were cut in thinkness stained with Haematoxilin – Eosin and examined under the microscope.

RESULTS

In 9 out of 1253 cases of appenddicitis, *Enterobius vermicularis* was revealed in pathology examination of histological material. The features of the cases are summarized in table-I . Localization of *E.vermicularis* in appendicitis are seen in figures 1 and 2.

DISCUSSION

Many cases of Extra-intestinal localization of *E.vermicularis* have been reported, Invasion of peritoneal cavity via the female reproductive system may result in the formation of abscess or granuloma around eggs or worms[4,5,6]. These are rarely of clinical significance, but have been thought to be responsible for a chronic pelvic peritonitis[7]. Abscess of perianal was reported by Corea[8] and extra–intestinal pinworm abscess associated with hernia by Tomieporth *et al*[9]. Adult worms of *E. vermicularis* or ova have been seen in vaginal smears[10-12] in urine[13] and even in macerated human embryo[14]. Cases of dysuria , nucturnal , enuresis[15]. epididymitis[16], central haemorrhagic chorioretinopathy of the left eye[17] due to *E.v* have been reported. Granuloma formation around pinworm egg in the liver was reported by little *et al* (1973)[18], Daly

Table-I : characteristics of patients with vermiform appendix

Case	*Sex*	*Age (year)*	*Perioperative diagnosis*	*Operative diagnosis*	*Report of surgical pathology*
1	F	19	Acute appendicitis	Appendix normal at gross pathology. Ovarian cyst	Veriform appendix with *E.v*. Ovarian luteal body cyst
2	M	8	Acute appendicitis	Acute suppurative appendicitis with perforation	Acute appendicitis with periappendicitis and E.v.
3	F	36	Acute appendicitis	Acute appendicitis	Early acute appendicitis infection of E.v
4	F	35	Acute appendicitis	Acute appendicitis ovarian cyst	Veriform appendix with E.v infection. Ovarian luteal body cyst
5	F	14	Acute appendicitis	Acute appendicitis	Unremarkable appendix with body and ova. of E.v
6	M	11	Acute appendicitis	Acute appendicitis	Appendix with dilated lumen containing E.v
7	F	34	Acute appendicitis	Acute appendicitis	Acute appendicitis with periappendicitis and E.v
8	M	18	Acute appendicitis	Acute appendicitis	Acute appendicitis with periappendicitis and E.v
9	M	13	Acute appendicitis	Acute appendicitis	Veriform appendix with E.v

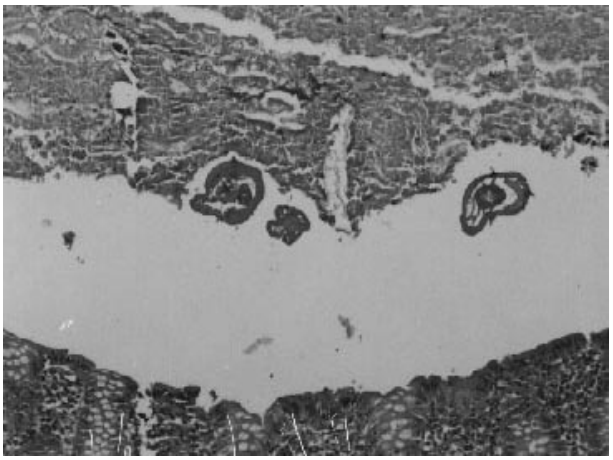

Fig. 1: Section of veriform appendix with *E. vermicularis*. H & E staining (100 ×)

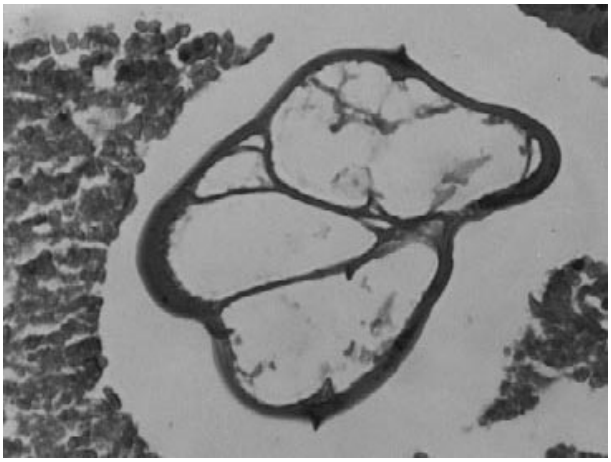

Fig. 2: Croos section of *E. vermicularis* . H & E staining (400 ×)

and Baker[19] Mondov and Gnepp[20]. An adult female pinworm found on thoracotomy for a non–calcified pulmonary nodule (Beaver *et al*) is thought to have grained access to peritoneal cavity via a necrotic area in an adenocarcinoma of the bowel[21]. Maraghi reported a case of pinworm in cerebrospinal fluid[22]. Chandrasoma and Mendis present evidence that pinworms are able to penetrate actively through the intact bowel wall[23]. Invasion of appendicitis may be expected to be the common occurrence, which it is, but relationship between this invasion and appendicitis remain unproved[24,25]. An association between histological findings of intramural parasites is recognized[26,27]. Budd and Armstrong reviewed 1419 appendicitis removed from cases of clinical appendicitis and 110 in other surgical procedures, *E. v* was identified in 2.7% of patients with clinical appendicitis[28].

Our study indicated that although intestinal enterobiasis is common in children but the cases of *E.v* found in appendicitis were seen in patients almost at the age of more than 14 and was most commonly seen in clinically acute appendicitis. During the operation of two female cases, ovarian cyst were revealed and at the same time, appendices were removed as well . Histopathological diagnosis was veriform appendix with *E.vermicularis* and leuteal ovarian body cyst in both of them. Mastuoke *et al* found that, when at histological examination he saw a normal appendix and the clinical diagnosis was chronic appendicitis, he would almost invariably find pinworm in the lumen of the appendix[29]. Others found pinworms in less than 1% of examined appendices[30,31]. Al Rabia et al reported 3% histologically proven cases of *Enterobious vermicularis* among 201 appendicectomy[32]. More recently, a study reviewing 2267 appendicitis showed that there was a highly significant differences in the incidence of *E.v* in normal appendices and inflamed appendicitis which may indicate that the presence of *E.v* in the appendix can give symptoms of acute appendicitis[24].

CONCLUSION

Our clinical and histopathological observation indicate that *Enterobius vermicularis* can cause acute appendicitis. *E.v* in appendix should be considered during the course of any other chronic pelvic inflammatory diseases, specially in women.

ACKNOWLEDGMENT

We wish to express our sincere thanks to the staff members at Departments of Surgery and Pathology, Imam Khomeini Hospital, Mr. A. Jelowdar, Department of Mycoparasitology, School of Medicine, Ahvaz , Iran, Mrs. Abiavi and Mr. R.Hayati for their assistance. All of them made this study possible.

REFERENCES

1. Russell LJ. The pinworm, *Enterobius vermicularis.* Prim Care 1991;18:13-24.
2. Brown HW, Neva FA. Basic clinical parasitology. 6th ed. Appleton century – crofts. New York 1994, pp. 128-32.
3. Markell EK, Voge M, John DT. Medical parasitology 6th ed. Saunders Company. London 1999, pp. 220-2.
4. Mattia AR. Perianal mass and recurrent cellulitis due to *Enterobius vermicularis.* Am J Trop Med Hyg, 1992; 47:811-5.
5. Mortensen NJ, Thomson JP. Perianal abscess due to *Enterobius vermicularis.* Report of 3 cases. Dis Colon Rectum 1984; 27:677-8.
6. Vafai M, Mohit P. Granuloma of the anal canal due to *Enterobius vermicularis,* Report of a case. Dis Colon Rectum 1983; 26:349-50.
7. Pearson RD, Irons RP Sr, Iron RP Ir. Chronic pelvic peritonitis due to pinworm, *Enterobius vermicularis.* J Am Med Assoc 1981; 245:1340-41.
8. Corea RT. *Enterobius Vermicularis* in an ectopic site perianal abscess. Ceylon Med J, 1983; 28:255-6.
9. Tomieporth NG, Disko P, Brandis A, Barutzki, D. Ectopic enterobiasis. A case report and review. J. Infect ,1992, 24,87-90
10. Demirezen S, Karayazgan Y. Eggs of *Enterobius vermicularis* in vaginal smears. Microbial. Bull, 1986; 20:290-4.
11. Mckay T. *Enterbius vermicularis* infection causing endometritis and persistent vaginal discharge in three siblings. N Z Med J, 1989; 102:56.
12. Deshpande AD. *Enterbius vermicularis* live adult worms in the high vagina. Postgrad Med J 1992; 68:690-91.
13. Adungo NI, Ondigo SO, Pamba HO. Observation of *Enterobius vermicularis* ova in urine, 3 cases reports. East Afr Med J 1989; 63:676-8.
14. Mendoza B, Jorda M, Rafel E, Simon A, Andrada E. Invasion of human embryo by *Enterobius vermicularis.* Arch Pathol Lab Med 1987; 111:761-2.
15. Gokalp A, Gultkin EY, Kirisci MF, Ozdamar S. Relation between *Enterobius vermicularis* infestation and dysuria, nocturia, enuresis. Nocturia and bacteriuria in primary school girl. Indian Pediatr 1991;28:948-50.
16. Kollias, G., Kyriakopoulos, M., Tiniakos, G. Epididymitis from *Enterobius vermicularis.* Case Report. J Urol 1992; 147:1114-6.
17. Schmidt D, Cony T. A case from practice. Eosinophilia in *Enterobius vermicularis* infection. Central haemorrhagic chorioretinopathy of the left eye. Schewiz Rundsch Med Prak 1990; 79:1308-10.
18. Little MD, Guello GJ, D" Alessandro A. Granuloma of the liver due to *Enterobius vermicularis.* Am J Trop Med Hyg 1973; 22:567-9.
19. Daly JJ, Baker GF. Pinworm granuloma of the liver. Am J Trop Med Hyg 1984; 33:62-4.
20. Mondou EN, Gnepp DR. Hepatic granuloma resulting from *Enterobius vermicularis.* Am J Clin Pathol, 1989;91:97-100.
21. Beaver PC, Kriz JJ, Lav TJ. Pulmonary nodule caused by *Enterobius vermicularis.* Am J Trop Med Hyg 1973; 22:711-3.
22. Maraghi S. *Enterobius vermicularis* in cerebrospinial fluid. Iranian Biomed J 1997; 1:49-51.
23. Chandrasoma PT, Mendis KN. *Enterobius vermicularis* in ectopic site. Am J Trop Med Hyg 1977; 26:644-9.
24. Wiebe K. Appendicitis and *Enterobius vermicularis.* Scand J Gastroenterol 1991; 26:336-8.
25. Baharkaran CS, Devi ES, Rao KV. *Enterobius vermicularis* of veriform appendix. J India Med Assoc, 1975;64:334-46.
26. Mogensen, K. *Enterobius vermicularis* and acute appendicitis. Acta Chir Scand 1985; 151:705-7.
27. Richmond HG, Guthrie W. *Enterobius vermicularis* of veriform appendix. J Pathol Bacteriol 1964; 87: 415-20.
28. Budd JS,Armstrong C. Role of *Enterobius vermicularis* in etiology of appendicitis. Br J Surg 1987; 74:748-9.
29. Masuoka Y. On the pathology of worm infction of veriform appendix. J Pathol Bacteriol 1916; 21:221-47.
30. Eterba JM. Appendiceal enterobiasis: its incidence and relationships to appendicitis. Folia Parasitol (praha), 1984; 31:311-8.
31. Colins DC. Study of 50000 specimens of the human appendix. Surg Gynecol Obstet 1955; 101:435-7.
32. Al Rabiah F, Halim MA, Ellis ME, Abdulkareem A. *Enterobius vermicularis* and acute appendicitis. Saudi Med J 1996; 17:799-802.