Original Article

REVIEW OF GRAY-SCALE ULTRASONOGRAPHIC FINDINGS: A VALUABLE GUIDE TO SUSPECT ADNEXAL TORSION

Maliheh Arab[1], Afsaneh Tehranian[2], Akram Ghara Mohammadi[3], Mojgan Hashemieh[4]

ABSTRACT

Objective: To report preoperative gray-scale sonographic characteristics of adnexal Torsion.

Methodology: In a retrospective multi-centric study in 20 hospitals, 148 out of 3303 adnexal mass operations, proved histopathologically as Adnexal Torsion, were reviewed regarding age, involved side and gray-scale abdominal sonographic findings.

Results: Torsion occurred in 5% of benign adnexal surgeries. Mean age was 29(SD=12), Mean mass diameter was 9 cm and they mostly revealed a cystic pattern (84%). Free peritoneal fluid was seen in 29%. Right-sided involvement was shown in 62%.

Conclusion: Gray-scale sonographic findings are valuable besides clinical findings to suspect adnexal Torsion.

KEY WORDS: Adnexal Torsion, Ovary, Ultrasonography, Adnexal mass.

Pak J Med Sci April - June 2010 Vol. 26 No. 2 300-303

How to cite this article:

Arab M, Tehranian A, Mohammadi AG, Hashemieh M. Review of gray-scale ultrasonographic findings: A Valuable guide to suspect Adnexal Torsion. Pak J Med Sci 2010;26(2):300-303.

INTRODUCTION

Torsion of ovary, tubes, or both is responsible for 2.7% of all gynecologic emergencies[1-2] regarded as the fifth most common gynecologic emergency at some series.[1] Adnexal torsion (AT) mostly occurs in child – bearing age groups, but it is not uncommon in premenarchal or postmenopausal women (17.2% of cases).[3] About 15% of ovarian torsions occur during childhood.[4]

Treatment of AT is considered to be an emergency because peritonitis and death can ensue. The presenting findings in most patients are nonspecific and unimpressive.[2] Ovarian torsion is a particularly challenging clinical diagnosis in children since children often cannot articulate their symptoms.[5-8]

The management of suspected AT is surgical untwisting of the mass and ovarian preservation which is particularly important in prepubertal and young women.[9] Sonography can be crucial in the correct diagnosis of this surgical emergency. Sonography is the modality of choice[3,10-12] in the evaluation of the female pelvis because it can be performed quickly, provides good visualization of pelvic organs, and

1. Dr. Maliheh Arab,
2. Dr. Afsaneh Tehranian,
3. Dr. Akram Ghara Mohammadi,
1-3: Department of Ob& Gynecology,
4. Dr. Mojgan Hashemieh,
Department of Pediatric Oncology,
1-4: Shahid Beheshti University of Medical Sciences, Tehran, Iran

Correspondence:

Dr. Maliheh Arab,
Associate Professor, Imam Hossein Hospital,
Madani (Nezamabad) St. Tehran, Iran
E-mail: drmarab@yahoo.com

* Received for Publication: September 15, 2009
* 1st Revised Received: September 24, 2009
* 2nd Revised Received: February 8, 2010
* Finial Revision Accepted: February 16, 2010

Table-I: Age, preoperative sonographic findings and side of Adnexal Torsion.

	Mean (±SD)	*Median (range)*	*Frequency N (%)*
Age	29 (±12)	26 (13-79)	–
Sono: size(cm)	9 (±3.6)	8 (2.1-35)	–
Sono:cystic			124 (84)
Sono: P.fluid(+)	–	–	43 (29)
Right sided	–	–	70 (62)¬

¬ The involved side was specified in 113 out of 148 cases.

involves no ionizing radiation to the patient.[13] The aim of this study was to report the preoperative gray-scale abdominal sonographic findings of adnexal torsion based on a retrospective multicenter review of pathologically proven torsion cases. We hope presenting these findings would increase clinicians awareness to pay more attention to diagnose AT which is usually delayed.

METHODOLOGY

We reviewed the medical records of all patients who were diagnosed with adnexal torsion in 18 tertiary and 2 secondary hospitals located in Tehran (17) and Hamadan (3), between 2000 and 2005. All 3303 reviewed patients were operated due to an adnexal mass bigger than 3 cm proved by gray-scale abdominal sonography. All the sonographists were in level two experience. Patients who were operated on for other causes except of Adnexal Torsion such as myoma, uterine prolaps, abnormal uterine bleeding or other causes were excluded. In the 148 individuals with clinical and histology proven adnexal torsion, we reviewed medical records. Age, ovarian mass size, echogenicity of the mass (solid – cystic), bilateral or unilateral, left or right sided, and existence of free fluid in the peritoneal cavity was recorded in a questionnaire. Analysis was done by version 13 of SPSS software.

RESULTS

Out of 3303 ovarian histopathology files, malignant and non-specified cases were excluded. The remaining 2961 benign diagnoses were included in the study. Of 2961 reviewed files, 148 (5%) ovarian torsion cases were identified.

Mean age of the patients with adnexal torsion was 29 (SD=±12) years old. In 113 out of 148 torsion cases, side of ovarian torsion was known. In 43 cases (38%), torsion was in the left side and in 70 (62%) patients; right sided adnexal torsion was documented. Mean diameter of the ovarian masses which were complicated with torsion in the studied cases was 9 cm (SD=±3.6) in preoperative sonography. Sonographic findings showed solid components in 24 out of 148 (16%) and free peritoneal fluid in 43 out of 148 (29%) (Table-I).

Of 148 ovarian torsion files, histopathology of the associated cyst was not reported in 70 cases. In the remaining 78 ovarian torsion files, histopathology of the cyst was documented. Simple cysts were the most common ovarian cysts in cases with torsion (41 out of 78 (52.5%)) followed by serous cystadenoma 14(18%), mucinous

Table-II: Age and sonographic findings according to histopathology in adnexal torsion.

	Freq. N(%)	*Age*		*Diameter (cm)*		*Solid*	*Free.P.fluid*
		Mean	*Median*	*Mean*	*Median*		
Simple cyst	41 (52)	25(±8)	25(13-46)	7.9 (±2.7)	7.9 (2.1-15.1)	3(4)	11(14)
Dermoid cyst	12 (15)	35(±13)	36(15-63)	8.6 (±4.3)	7.8(4.9-20)	4(5)	5(6)
Serous cystad.	14 (18)	31 (±14)	27(13-59)	11.5 (±7.7)	9.7(5.1-35)	0	5(6)
Mucinous cystad.	11 (14)	45 (±21)	42(20-79)	13.8 (±3.8)	14.3(8-20)	1(1)	2(2.5)
Total	78 (100)						

¬Sums are presented as mean (± SD), median (range) and frequency: N(%).

Table-III: Comparison of age, preoperative sonographic findings and side of adnexal torsion between different studies

Study	*Age*			*size*		*Echo pattern*			
	No.	*Mean*	*Median*	*Mean*	*Median*	*Solid*	*Cystic*	*Free fluid*	*Right-sided*
Present study	148	29(±12)	26(13-79)	9(±3.6)	8(21-35)	24(16)	124(84)	43(29)	70(62)
Study A (13)	74	—-	11(0.1-21)	—-	—-	5(12)	69(88)	12(39)	25(61)
Study B (16)	34	—-	26(12-46)	7.4(±2.6)	(3-14.1)	9(17)	24(73)	—-	—-
Study C (17)	14	17	(0.1-54)	—-	—-	2(14)	12(86)	—-	—-
Study D (18)	102	22.7	(2.5-38)	7.5(±3)	—-	—-	—-	—-	—-
Sstudy E (19)	21	—-	—-	5.4	—-	—-	—-	—-	15(71)

¬ Sums are presented as mean (± SD), median (range), and frequency N(%)

cystadenoma 11(14.5%) and dermoid cysts 11(14.5%).

In none of the 177 patients, histopathology of endometrioma or bilateral torsion was reported. Frequency, age, sonographic findings including mass diameter, cystic/solid pattern and free peritoneal fluid according to histopathology is shown in Table-II.

In our study, the probability of torsion was highest in mucinous cystadenoma, as torsion was seen in 11 out of 222 mucinous histologies (5%), followed by dermoid cysts, serous cystadenoma and functional cysts (Fig-I).

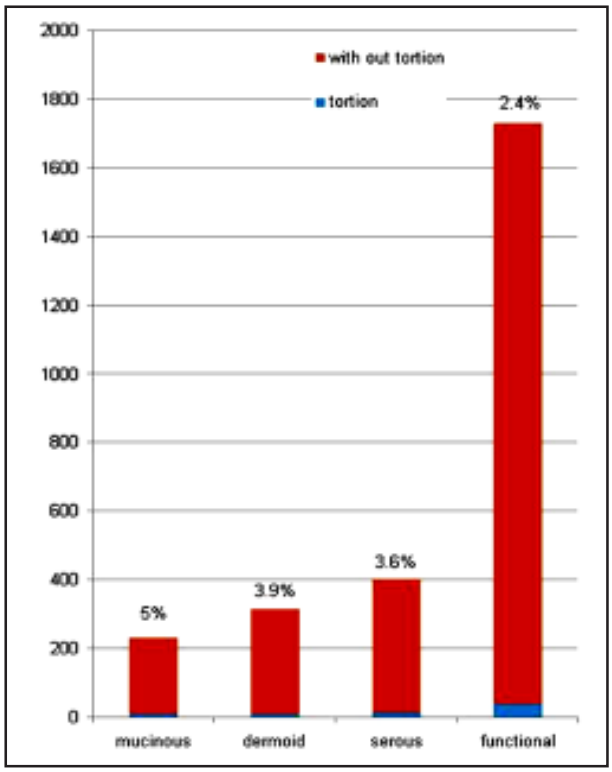

Fig-1: Probability of torsion in benign ovarian histologies

DISCUSSION

Adnexal torsion can occur at all ages but is more often seen in women of reproductive age (70.6% from 20 to 39 years).[1] Mean and median age of AT in our study and 5 other studies was below 30 years of age (Table-III). Adnexal torsion is almost always associated with an enlarged ovarian mass.[11,13-15] On the other hand, venous flow, as the first compromised flow due to compressibility of these low pressure vessels, results in congestion and edema of ovary and makes ovary larger.

The mean size of the ovarian mass in our study and other reviewed studies were 9, 7, 7 and 5cm (Table-III). The associated ovarian mass was mostly cystic in our study (84%) and other reports (88%, 73%, 86%) (Table-III). Masses which were complicated with torsion showed a solid pattern in 12-17% of the cases. A solid mass pattern correlates with the pathologic findings of vascular engorgement and stromal edema.[17,20]

A variable amount of pelvic fluid can be present[3]; however, in all of these cases, the amount of fluid was small in quantity.[13] In our study 29% and in the another study 30% of the cases revealed free fluid in peritoneal cavity.

Adnexal torsion shows a right – sided predominance with a ratio of approximately 3:2 reported in the literature.[21] The propensity for right-sided involvement has been thought to be due to the decreased space in the left side of the lower abdomen and pelvis which is occupied by the sigmoid colon.[22] It is said that the differences in venous drainage of the two ovaries may also be a factor in the propensity for right–sided torsion.[23]

Right–sided predominance has been confirmed in our study (62%) and 2 other studies (61%, 71%) (Table-III). Torsion is rare after pelvic inflammatory disease and endometriosis due to associated pelvic adhesions even in cases with endometrioma.[3] We had no cases of endometrioma in our study. Simple cysts were the most common ovarian cysts in cases with torsion (52%) but the probability of torsion in simple cysts was the lowest (2.4%) (Fig-I). It seems that due to the high prevalence of simple cysts, its absolute rate is high in AT cases.

The most common ovarian cyst associated with AT in some other reviewed studies are as follows: dermoid cysts in three[11,14,16], dermoid cysts followed by simple cysts in three[10,13,24] and simple cysts followed by dermoid cysts in two studies-[3-18]

Our study, in spite of being a large multicentric study, has several limitations. It was a retrospective review and the patients were not studied by a strict sonographic protocol searching for torsion due to clinical suspicion. Data was obtained from different ultrasound operators, although all were in level two experience. Doppler sonography was not done for these patients.

Despite the limitations of the study, we conclude that preoperative gray-scale sonographic features are valuable in adnexal torsion. Clinical findings in a young woman with a lower abdominal pain and an adnexal mass of about 7-8cm make sonographic findings more specific for clinician to be more suspicious about Adnexal Torsion in the differential diagnosis list. Adnexal Torsion as an emergency is usually underdiagnosed. We hope clinicians become more sensitive to simple sonographic findings of AT and according to the specific available apportunities in the working place order a referral gray-scale sonography by an expert sonographer (level 3) and / or Doppler sonography.

Author Contribution: M.A, designed, collected data, analyzed and wrote draft of article and revised it.AT, AG and MH helped in data collection, revised manuscript and approved it.

REFERENCES

1. Hibbard LT. Adnexal torsion. Am J Obstet Gynecol 1985;152:456-61.
2. Rock JA, Jones HW. Telinde's operative gynecology 10th ed. Lippincott Williams & Wilkins 2008;637-8.
3. Bertolotto M, Serafini G, Toma P, Zappetti R, Migaleddu V. Adnexal torsion. Ultrasound Clin 2008;3:109-119.
4. Descargues G, Tinlot – Manger F, Gravier A. Adnexal torsion: A report on forty – five cases. Eur J Obstet Gynecol Reprod Biol 2001;98:91-96.
5. Graif M, Itzchak Y. Sonographic evaluation of ovarian Torsion in childhood and adolescence. AJR 1988;150:647-649.
6. Farrell TP, Boal DK, Teele BL. Acute torsion of normal uterine adnexa in children: Sonographic demonstration AJR 1982;139:1223-1225.
7. Evans JP. Torsion of the normal uterine adnexa in premenarchal girls. J Pediatr Surg 1978;13:195-196.
8. Schulz LR, Newton WA, Clatworthy HW. Torsion of previously normal tube and ovary in children. N Engl J Med 1963;268:343-346.
9. Berek JS. Berek & Novak's Gynecology.14th ed. Lippincott Williams & Wilkins 2007:482.
10. Michael D. Ovarian torsion. Semin Pediatr Surg 2005;14(2):86-92.
11. Akata D. Ovarian torsion and its mimics. Ultrasound Clinics 2008;3(3):451-460.
12. Mazouni C, Bretelle F, Menard JD, Blanc B, Gamerre M. Diagnosis of adnexal torsion and predictive factors of adnexal necrosis. Gynecol Obstet Fertil 2005;33:102-106.
13. Servaes S, Zarakowski D, Laufer MR, Feins N, Chow JS. Sonographic findings of ovarian torsion in children. Pediatr Radiol 2007;37:446-451.
14. Grant DE, Mewilliams DO, Micah J, Hill Do, Charles S, Dietrich III. Gynecologic emergencies. Surg Clin N Am 2008;88:265-283.
15. Breech LL, Hillard PJ. Adnexal torsion in pediatric and adolescent girls. Curr Opin Obstet Gynecol 2005;17:483-489.
16. Dane B, Dane C, Kiray M, Cetin A. Sonographic findings in adnexal Torsion: A report of 34 cases. Archives of Gynecol Obstet 2008;279(6):841-844.
17. Warner MA, Fleischer AC, Edell SL, Thieme GA, Bundy AL, Kartz AB, et al. Uterine Adnexal torsion: Sonographic findings. Radiology 1985;154:773-775.
18. Oelsner G, Cohen SB, Soriano D, Admon D, Mashiach S, Carp H. Minimal surgery for the Twisted ischemic adnexa can preserve ovarian function. Human Reproduction 2003;18(12):2599-2602.
19. Pena JE, Ufbery D, Cooney N, Denis AL. Usefulness of Doppler sonography in the diagnosis of ovarian torsion. Fertile Steril 2000;73(5):1047-1050.
20. Lesley L, Adams Hillard BJ, Adams Hillard PJ. Adnexal Torsion in pediatric and adolescent girls. Current opinion Obstet Gynecol 2005;17:483-489.
21. Manos TN, Torsion of uterine adnexa: Report of a case in a girl three years old. Ohio Med J 1954;550:559.
22. Sebastian JA, Baker RL, Cordray R. Asymptomatic infarction and separation of ovary and distal uterine tube Obstet Gynecol 1974;41:531-535.
23. Kanbour AL, Salazar H, Tobon H, Massive Ovarian edema. Arch Pathol Lab Med 1979;103:42-45.
24. Rody A, Jackisch C, Klockenbuseh W, Heinig J, Coenen – worch V, Schneider HPG. The conservative management of adnexal totsion – A case – report and review of the literature. Eur J Obstet Gynecol Rep 2002;101:83-86.