

COMPARATIVE STUDY OF AMINOGLYCOSIDES (GENTAMICIN & STREPTOMYCIN) AND FLUOROQUINOLONE (OFLOXACIN) ANTIBIOTICS ON TESTIS TISSUE IN RATS: Light and Transmission Electron Microscopic Study

Arash Khaki¹, AmirAfshin Khaki², Sohrabihaghdost Iraj³, Parviz Bazi⁴,
Seyed Amir Mahdi Imani⁵, Homan Kachabi⁶

ABSTRACT

Objective: To investigate the comparative effects of aminoglycosides and fluoroquinolones on testis structure and serum testosterone hormone level in rats.

Methodology: Forty male Wister rats were randomly divided into control (n=10) and experimental (n=30) groups. The experimental groups were subdivided into three groups of ten. Each received 5 mg/kg (IP) Gentamicin, 40mg/kg (IP) Streptomycin and 72mg/kg (IP) Ofloxacin daily for 14 days, respectively; however, the control group just received vehicle (IP). In the fourteenth day, 5cc blood was collected for testosterone hormone then rats were killed and testis tissues were also prepared for light and electron microscopic study.

Results: Depletion of germ cells, germinal cells necrosis, especially in spermatogonia, and Leydig cells had an abnormal fibroblast-like appearance. Abnormal space between neighbour sertoli cells, mitochondria were lost cristae and vacuolated (none energized), lysosome seen more in cytoplasm of sertoli cells and Veins congestion were seen in gentamicin & ofloxacin groups. These side effects were seen fewer in Streptomycin group.

Conclusions: Gentamicin, Streptomycin and Ofloxacin have negative effects on testis architecture and germinal cells damages in rats. However, these side effects are seen less in the Streptomycin group. Therefore, it is recommended that usage of this drug have fewer side effects on male fertility.

KEY WORDS: Gentamicin, Streptomycin, Ofloxacin, Testosterone, Testis.

Pak J Med Sci July - September 2009 Vol. 25 No. 4 624-629

How to cite this article:

Khaki A, Khaki AA, Iraj S, Bazi P, Imani SAM, Kachabi H. Comparative Study of Aminoglycosides (Gentamicin & Streptomycin) and Fluoroquinolone (Ofloxacin) Antibiotics on Testis Tissue in Rats: Light and Transmission Electron Microscopic Study. Pak J Med Sci 2009;25(4):624-629.

Correspondence

Arash Khaki
Department of Veterinary Pathology (YRC),
Islamic Azad University Tabriz Branch,
Tabriz - Iran.
E-mail: arashkhaki@yahoo.com

- * Received: October 7, 2008
- * Revision Received: June 11, 2009
- * Revision Accepted: July 8, 2009

INTRODUCTION

A review of pharmacological therapy in male infertility shows modern therapy is based on three pharmacological groups of compounds: gonadotropins, androgens and kininogenases, the latter releasing pharmacologic active kinin peptides from kininogen. In addition, antiestrogens and gonadotropin-releasing hormones seem to be promising agents for the near

future. The use of antibiotics is of great importance in the therapy of male genital tract infections which often leads to a reduced fertility.

Antibiotics are commonly prescribed for a variety of diseases. Some patients requiring assisted conception occasionally show evidence of infection of the male reproductive tract.¹ The antibiotic aminoglycosides (Gentamicin, neomycin, Streptomycin) and fluoroquinolones (Ofloxacin) are routinely used by fertility specialists to treat such bacterial infections occurring prior to in vitro fertilization treatment, or when high concentration of leukocytes are present in the semen of these patients, irrespective of microbial evidence of infection. In the laboratory, aminoglycosides are commonly used in embryo culture, sperm wash and cryopreservation media for controlling growth of bacteria and fungi. The most frequently used antibiotics are Streptomycin sulfate and penicillin.² In vivo and in vitro genotoxicity studies suggest these antibiotics as safe for therapeutic use.³ However, other studies have demonstrated they impair significantly both testicular function and structure.^{4,5} Recently we have reported that Ciprofloxacin, Gentamicin, neomycin, Streptomycin and Ofloxacin results in apoptosis in testis⁶. The aim of the present study was to compare the effect of Gentamicin, Streptomycin and Ofloxacin on structural of testis in rat.

METHODOLOGY

Animals: Forty adult Wister albino male rats were 8 weeks old and weighing 250 ± 10 g. They were obtained from animal facility of pasture institute of Iran. Male rats were housed in temperature controlled rooms (25°C) with constant humidity (40-70%) and 12h/12h light/ dark cycle prior to use in experimental protocols. All animals were treated in accordance to the Principles of Laboratory Animal Care. The daily intake of animal water was monitored at least one week prior to start of treatments in order to determine the amount of water needed per experimental animal. Thereafter, the rats were randomly selected and divided into

control (n=10) and experimental (n=30) groups. The experimental groups were subdivided in four groups of ten. Each received 5 mg/kg (IP) Gentamicin, 40mg/kg (IP) Streptomycin and 72mg/kg (IP) Ofloxacin daily for fourteenth days, respectively; however, the control group just received vehicle (IP).

Surgical Procedure: On the fourteenth day, the Pentobarbital sodium (40 mg/kg) was administered intra peritoneally for anesthesia, and the peritoneal cavity was opened through a lower transverse abdominal incision. Then testis and epididymis were immediately removed. The weights of testis in both groups were recorded. At the end of the experiment; the animals were anesthetized with diethyl ether and killed by decapitation.

The testis were fixed in 10% formalin and embedded in paraffin. Five-micron thick sections were prepared and stained with hematoxylin and eosin (H&E). For transmission electron microscopy (TEM) the testis samples were cut into piece (2×2mm) and fixed in 2.5% glutaraldehyde (PH=7.4) for 6-8 hour at 4 °C. They were washed and post fixed in 2% OsO_4 for one hour, at 4°C. The tissue was dehydrated through ascending grades of ethanol and embedded in araldite CY212. Semi thin sections (1µm) were cut and stained with toluidine blue. Ultra thin sections (60-70nm) were cut, and stained with uranyl acetate and alkaline lead citrate.

Serum concentration of total testosterone: Hormone was measured using a double antibody RIA (commercial available kit) from Immunotech Beckman Coulter Company. The sensitivities of hormone detected per assay tube were 0.025ng/ml.⁷

Statistical analysis was done using the ANOVA and Chi-square tests for comparison of data in the control group with the experiment groups. The results were expressed as mean \pm S.E.M (standard error of means). *P* value less than 0.05 were considered significant.

Table-I: Results of Serum Total Testosterone hormones measurement

Groups	Control	Gentamicin	Streptomycin	Ofloxacin
Serum testosterone Level (ng/mL serum)	3.6 ± 0.13	1.4 ± 0.06*	1.6 ± 0.05*	1.1 ± 0.04*

Values are mean ± SE

*Significant different at $P < 0.05$ level, (compared with the control group).

RESULTS

Light Microscopic: Histopathological study showed that the cycle of spermatogenesis was regular in the control group (Figure-1: A). However, in all animals exposed to drugs depletion of germ cells were seen, germinal cells necrosis, especially in spermatogonia, evidence of cell debris in lumen and presence of lymphocyte and plasmocyte (except Streptomycin group) (Figure1:B). Expansion of interstitial space and intertubular space with vacuolization was developed and Leydig cells had an abnormal fibroblast-like appearance. Fibroblastic degeneration appeared in somniferous tubules and congestion in veins were increased in all experimental groups as compared with those seen in the control group (Figure1:C).

Transmission Electron microscopic: In control group Spermatogonia cells were normal (Ea), primary spermatocyte mitochondria seemed normal with cristae (Eb), Nucleus was euchromatin and Cytoplasm organelles and Nucleus of myoied cell were normal (Ec), (Figure 1: Ea,Eb,Ec).

In Gentamicin group histopathological changes were: Abnormal space between neighbour sertoli cells, mitochondria were lost cristae (none energized), (Fa). lyzosome seen more in cytoplasm of sertoli cells, Nucleus of myoied cell was done heterochromatin (Fb), (Figure 1: F).

Total Testosterone level decreased significantly ($P < 0.05$) in animals who received drugs in comparison to control group (Table-I).

In Ofloxacin group histopathological changes were: Mitochondria were vacuolated and vacuoles were abundant in cytoplasm of primary spermatocyte (Ja), Nucleus substances were fragmented in primary spermatocyte and increased germ cell degeneration and condensation of germ cell nuclei. Nucleus was hetero-

chromatin in spermatogonia, endoplasmic reticulum systems were dilated and it seemed first stage of cell damage (Jb). (Figure-1: Ja,Jb). In Streptomycin group histopathological changes were: vacuolization demonstrated in cytoplasm of primary spermatocyte. (Figure-1: H).

DISCUSSION

Evidence-based drug therapy for male infertility is often difficult because 30% of all cases of male infertility are classified as idiopathic

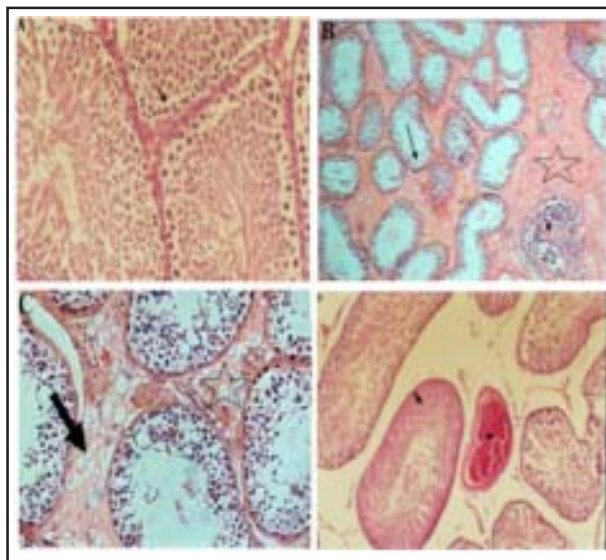
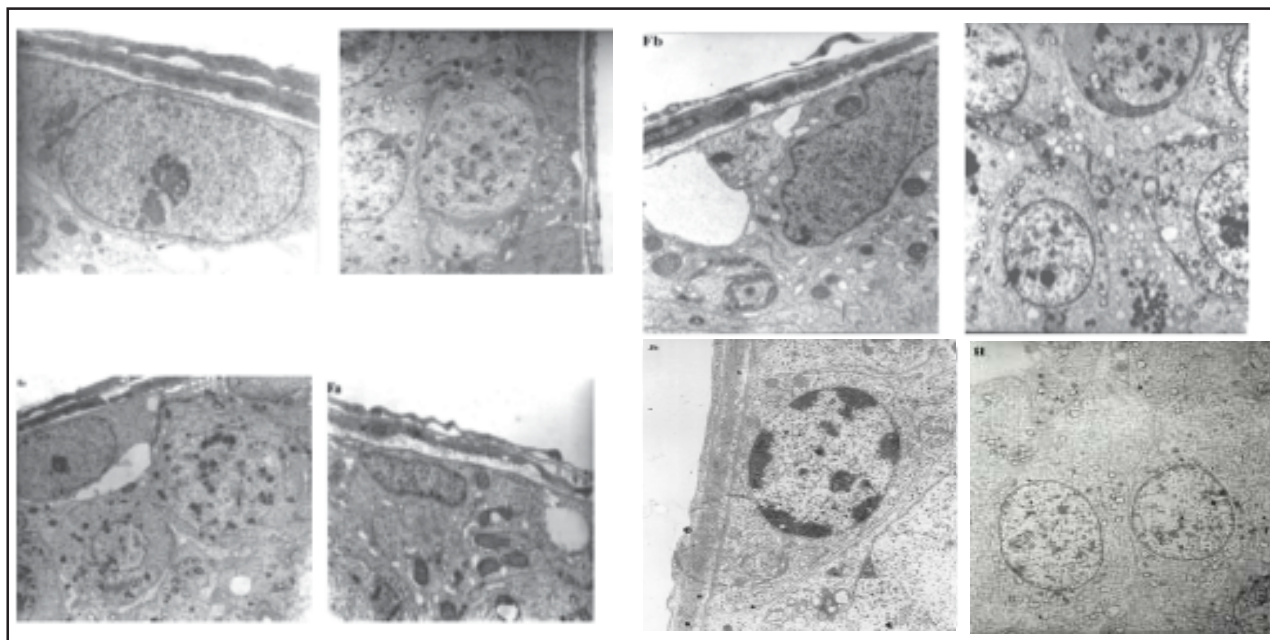


Fig-1: Photomicrograph of testis in control group show regular epithelium seminiferous layers (arrow), H&E (A), X40. Photomicrograph of testis in Gentamicin group show depletion of germ cells, germinal cells necrosis (arrow) and presence of lymphocyte and plasmocyte (triangle), Expansion of interstitial space with fibrosis were seen (star) (H&E) method (B), X40. Photomicrograph of testis in Ofloxacin group show expansion of interstitial space (star) with vacuolization of tubular interstitial space in (arrow) (H&E) method (C), X40. Photomicrograph of testis in the Streptomycin group show congestion in vein (star) and fibrinoid degeneration seminiferous tubule (arrow) with tubular detached (H&E) method (D), X40.



Transmission Electron microscopic (TEM) Photomicrograph of testis in control group: Spermatogonia cells were normal (**Ea**), (X5000). Primary spermatocyte mitochondria seemed normal with cristae (**Eb**), (X5000). Nucleus was euchromatin and Cytoplasm organelles and Nucleus of myoid cell were normal (**Ec**), (X5000). (**Figure 1: Ea, Eb, Ec**). In Gentamicin group histopathological changes were: Abnormal space between neighbor sertoli cells, mitochondria were lost cristae (none energized), (**Fa**) (X5000). lysosomes seen more in cytoplasm of sertoli cells, Nucleus of myoid cell was done heterochromatin (**Fb**), (X). (**Figure-1: F**). In Ofloxacin group histopathological changes were: Mitochondria were vacuolated and vacuoles were abundant in cytoplasm of primary spermatocyte (**Ja**), (X5000). Nucleus substances were fragmented in primary spermatocyte and increased germ cell degeneration and condensation of germ cell nuclei. Nucleus was heterochromatin in spermatogonia, endoplasmic reticulum systems were dilated and it seemed first stage of cell damage (**Jb**), (X5000). (**Figure 1: Ja, Jb**). In Streptomycin group histopathological changes were: vacuolization demonstrated in cytoplasm of primary spermatocyte, (X5000). (**Figure 1: H**).

and another 30% need surgical treatment. Without knowledge of the underlying pathology, there is no foundation for a specific and causal treatment.¹ Drug treatment, chemotherapy, toxins and environmental factors, can have harmful effect on spermatogenesis and affect sperm normal production.⁸ Most of the currently used drug therapies are empirical at best; moreover, many of the studies on drug treatment for male infertility do not fulfill the required standards of evidence-based medicine (randomized, prospective, placebo controlled).¹

In the present study, all four different antibiotics were tested, Ofloxacin and Gentamicin and Streptomycin, had adverse effect on testis tissue in rats. Our prior studies had showed that, Gentamicin, Neomycin and Streptomycin, Ofloxacin and Ciprofloxacin have nega-

tive effects on sperm parameters and cause testis germ cells apoptosis in rats. However these side effects are less seen in the Streptomycin group.⁶ Some studies show that Ofloxacin at a dose of 72mg/kg, showed almost the highest potential in terms of impairment of the rat testicular functions.⁴ It is reported that sperm was significantly decreased after 50 days when Ofloxacin was administered to patients in a dose of 200 mg two times daily for 20 days.⁹ On the other hand, it has shown that Ofloxacin in rats revealed testicular impairment, indicated by decreased haploid cells at days 11 and 56 from starting the treatment using flow cytometric analysis of testicular aspirate.¹⁰ Our study is also comparable to another study which obtained similar results with a slightly different concentration of Ofloxacin.¹² More-

over, it has been shown that sperm motility was not affected by Ofloxacin in a concentration up to 4.5 mg/l as tested on fresh ejaculate of andrologic patients.^{11,13} Our light and transmission electron microscopic result indicated, that all animals exposed to drugs saw a depletion of germ cells, germinal cells necrosis, especially in spermatogonia, evidence of cell debris in lumen and present of lymphocyte and plasmocyte (except Streptomycin group). Expansion of interstitial space and intertubular space with vacuolization, degeneration, fibrosis and necrosis of interstitial (Leydig) cells following exudation into the interstices was developed and congestion in veins were increased in all experimental groups. These are seen less in the Streptomycin group as compared with those seen in the control group, and these data's were confirmed in our previous study.⁶ Testosterone assay showed decreased hormone levels in all drugs groups and seems the necrosis of the interstitial cells probably would have resulted in decreased synthesis of this hormone. They observed abnormal space between neighbor sertoli cells and heterochromatin Nucleus of Myoid cell may indicate cooperation sertoli cells and Myoid cells in regulative and defensive response and form a barrier to toxic substance of external origin. Oxidative stress plays a critical role in the etiology of defective sperm formation, function; sperm count profile and male infertility.¹⁴ Some studies have shown that Ciprofloxacin treatment for 15 and 60 days in rats resulted in a marked reduction in sperm parameters.^{4,6} These results are possibly due to an increased peroxide radical generation in the testis following Ciprofloxacin and Ofloxacin treatment,^{12,15} which then induces DNA single-strand breaks and chromosomal aberrations as demonstrated by in vitro genotoxicity studies.¹⁶ It is now well known that Gentamicin is severely ototoxic and it seems to be due to oxidative stress.⁶ Our Transmission Electron microscopic in Gentamicin group showed that mitochondria were lost cristae and lysosome was seen more in cytoplasm of sertoli cells, Nucleus of myoid cell was done heterochromatin and this has con-

firmed stage of cell death and is similar as reported in other studies.^{6,12} Gentamicin is also known to inhibit the activities of phosphatases in the reproductive organs and decrease in sperm count, motility, viability, germ cell apoptosis, Ascorbic acid, steroidogenic enzymes and cholesterol levels^{6,9} and decreased antioxidant levels in testis.¹⁷ Histopathological changes such as epithelial cell sloughing, atrophic changes and decrease in germ cell numbers due to cytotoxicity were the factors responsible for decrease in the testis weight and this relation has been very well established in various other experimental conditions.¹⁷ Degenerative changes in the seminiferous tubules and decrease of spermatozoa in the testis, epididymis and vas deferens are the evidence for genotoxicity.

These results indicate that Gentamicin, Streptomycin and Ofloxacin look like as other chemical agents may directly interfere in the process of spermatogenesis. This increase in germ cell apoptosis and cell damage is possibly due to an increased peroxide radical generation in the testis following Ofloxacin treatment.¹⁴ In addition, Ofloxacin could activate Caspases 3 and induce apoptotic pathways. Our results showed that aminoglycosides had an adverse effect on spermatogenesis. These were in agreement with our other studies that showed Gentamicin and Ofloxacin antibiotics have negative effect on testis Architecture in rats.¹⁸ Therefore studies using rats treated with therapeutic doses of Gentamicin confirmed the observations in humans regarding the adverse effects of aminoglycosides on spermatogenesis.¹⁶ These animals were found to have spermatogenic arrest with cessation of spermatogonial division and interruption of meiosis in primary spermatocytes. All antibiotics used in the present study had negative effect on spermatogenesis, distinct signs that the spermatogenesis process had been arrested or greatly impaired. It has been reported that individually, Penicillin, Streptomycin and Gentamicin did not affect embryo development in vitro.⁹

In conclusion, aminoglycosides and fluoroquinolone antibiotics have negative

effect on sperm parameters and testis architecture in rats. However, these side effects are less seen in the Streptomycin group. Therefore, it is recommended that usage of this drug have fewer side effects on male fertility.

ACKNOWLEDGMENT

We thank the staff at Islamic Azad University of Tabriz for their help and support in the preparation of this manuscript.

REFERENCES

1. Oliva A, Giami A, Multigner L. Environmental agents and erectile dysfunction: a study in a consulting population. *J Andrology* 2002;(23):546-550.
2. Magli MC, Gianaroli L, Fiorentino A, Ferraretti AP, Fortini D, Panzella S. Improved cleavage rate of human embryos cultured in antibiotic-free medium. *Hum Reprod* 1996;(11):1520-1524.
3. Herbold BA, Brendler-Schwaab SY, Ahr HJ. Ciprofloxacin: in vivo genotoxicity studies. *Mutat Res* 2001;(498):193-205.
4. Abd-Allah AR, Aly HA, Moustafa AM, Abdel-Aziz AA, Hamada FM. Adverse testicular effects of some quinolone members in rats. *Pharmacol Res* 2000;(41):211-219.
5. Demir A, Turker P, Onol FF, Sirvanci S, Findik A, Tarcan T. Effect of experimentally induced *Escherichia coli* epididymo-orchitis and Ciprofloxacin treatment on rat spermatogenesis. *Int J Urol* 2007;(14):268-72.
6. Khaki A, Heidari M, Ghaffari Novin M, Khaki AA. Adverse effects of Ciprofloxacin on testis apoptosis and sperm parameters in rats. *Iranian J Reproductive Medicine* 2008;(6):71-76.
7. Huang HFS, Linsenmeyer TA, Li MT, Giglio W, Anesetti R, von Hagen J, et al. Acute effects of spinal cord injury on the pituitary-testicular hormone axis and Sertoli cell functions: a time course study. *J Androl* 1995;(16):148-157.
8. Haidl G, Schuppe HC, Köhn FM, Leiber C. Evidence-based drug therapy for male infertility. *Urologe A* 2008;47(12):1555-6.
9. Andreessen R, Sudhoff F, Borgmann V, Nagel R. Results of Ofloxacin therapy in andrologic patients suffering from therapy-requiring asymptomatic infections. *Andrologia* 1995;(25):377-383.
10. Crotty KL, May R, Kulvicki A, Kumar D, Neal DE Jr. The effect of antimicrobial therapy on testicular aspi-
rate flow cytometry. *J Urol* 1995;(153):835-838.
11. Schramm P. Ofloxacin: concentration in human ejaculate and influence on sperm motility. *Infection* 1986;(14):274-275.
12. King K, Chan PJ, Patton WC, King A. Antibiotics: effect on cryopreserved-thawed human sperm motility in vitro. *Fertil Steril* 1997;(67):1146-1151.
13. Khaki A, Ghaffari Novin M, Khaki AA, Nouri M, Sanati E, Nikmanesh M. Comparative study of the effects of Gentamicin, neomycin, Streptomycin and Ofloxacin antibiotics on sperm parameters and testis apoptosis in rats. *Pak J Biological Sci* 1998;(8):35-41.
14. Shen H, Ong C. Detection of oxidative DNA damage in human sperm and its association with sperm function and male infertility. *Free Radic Med Biol* 2000;(28):529-36.
15. Weyers AI, Ugnia LI, García Ovando H, Gorla NB. Ciprofloxacin increases hepatic and renal lipid hydroperoxides levels in mice. *Biocell* 2002;(26):225-228.
16. Sanchez G, Hidalgo ME, Vivanco JM, Escobar J. Induced and photoinduced DNA damage by quinolones: Ciprofloxacin, Ofloxacin and nalidixic acid determined by comet assay. *J Photochem Photobiol* 2005;(81):819-822.
17. Narayana K. An aminoglycoside antibiotic gentamycin induces oxidative stress, reduces antioxidant reserve and impairs spermatogenesis in rats. *J Toxicol Sci* 2008;(33):85-96.
18. Khaki A, Ghaffari Novin M, Khaki AA, Fathiazad F, Khaberi M, Hossinchi J, et al. Ultra structural study of gentamicin and ofloxacin effect on testis tissue in rats: Light and transmission electron microscopy. *Afr J Pharmacy Pharmacology* 2009;(4):105-109.

Authors:

1. Arash Khaki,
Department of Veterinary Pathology (YRC),
 2. AmirAfshin Khaki,
Department of Anatomical Science,
Tabriz University of Medicine Science,
National Management Center for Health [NPMC],
Tabriz, Iran.
 3. Sohrabihaghdost Iraj,
Department of Veterinary Pathology,
Islamic Azad University Sciences,
Research Branch, Tehran - Iran.
 4. Parviz Bazi,
Department of Anatomical Science,
Boushehr University of Medicine Science.
 5. Seyed Amir Mahdi Imani,
Department of Veterinary Pathology (YRC),
 6. Homan Kachabi,
Department of Veterinary Pathology (YRC),
- 1,4-6: Islamic Azad University Tabriz Branch,
Iran.