

Diagnosis and treatment of carotid body tumors

Halil Basel¹, Hasan Ozturk², Cemalettin Aydin³,
Cemil Goya⁴, Ekrem Bayar⁵

ABSTRACT

Objective: Carotid body tumors (CBTs), especially familial paragangliomas, are rare benign neoplasm, accounting for <0.5% of all tumors; and they are the most common extra-adrenal paraganglioma. Because of peripheral vascular and neural invasion or compression of tumors, early diagnosis and treatments are very important, whereas this kind of tumors have got slow progression and low malignity potential. The aim of this study was to review an institutional experience in the management of paragangliomas.

Methodology: In this study, CBTs were clinically suspected in 33 patients but diagnosed by histopathology in between 1999 and 2011 at our department. Three of these patients presented with bilateral tumors. All but one was operated upon. The ages of the 48.3 surgically treated patients ranged 32-58 years. A mass in the neck was the common symptom in all patients. The patients were classified according to the Shamblin classification. There were 17 patients (11 women 6 men) in the first group, 13 patients (9 women, 4 men) in the second group, and 3 patients (2 women 1 man) in the third group.

Results: All of these 33 surgically treated patients had confirmed CBT by histopathology. CBTs were resected without a shunt procedure. No mortality occurred, however one patient experienced Horner syndrome post operatively. In the follow up period, no recurrences were observed. Three of the patients was had hoarseness, but improved after six months. No stroke occurred in the patients.

Conclusion: CBTs are infrequent neoplasm; their surgical treatment is highly dependent on the ability and experience of the surgeon. The diagnostic and therapeutic relevance reside in making a timely diagnosis to propose a surgical treatment aimed at preventing complications and neurological damage. Surgical resection is usually definitive therapy for these lesions.

KEY WORDS: Carotid Body Tumor; Carotid Arteries; Cranial Nerve Diseases.

Pak J Med Sci July - September 2011 Vol. 27 No. 4 797-801

How to cite this article:

Basel H, Ozturk H, Aydin C, Goya C, Bayar E. Diagnosis and treatment of carotid body tumors. Pak J Med Sci 2011;27(4):797-801

1. Halil Basel, MD,
2. Hasan Ozturk, MD,
3. Cemalettin Aydin, MD,
4. Cemil Goya, MD,
5. Ekrem Bayar, MD,

Correspondence:

Halil Basel, MD,
Department of Cardiovascular Surgery,
Bezmi Alem Vakif University, Turkey.
E-mail: hbasel@mynet.com
hbasel1966@hotmail.com

- * Received for Publication: March 4, 2011
- * Revision Received: March 17, 2011
- * Second Revision: May 30, 2011
- * Final Revision Accepted: June 16, 2011

INTRODUCTION

Carotid body tumors (CBTs), also known as paragangliomas, are among the tumors of neuroectodermal origin. Paragangliomas arise from parasympathetic nerves and may develop at any site from the skull base to the arch of aorta. They are most frequently seen in the "carotid body". Carotid body tumors are rare and slowly growing tumors, which are generally benign and asymptomatic. Moreover, they demonstrate familial tendency, local lymph node (LN) invasion and distant metastasis in 10% of the cases.¹ Although they are asymptomatic when they are small in size, they lead to symptoms such as

dysphagia, dysphonia (voice disorder), cough, tinnitus, hearing loss, headache, vertigo, bradycardia and syncope related particularly to the pressure on N. glossopharyngeus, N. vagus and N. hypoglossus, as they grow. Vocal cord paralysis, sympathetic nerve involvement as well as Horner's syndrome may occur. Unless carotid body tumors involve the carotid bifurcation, they are not pulsatile. They are generally mobile in a radial fashion around the axis of the carotid artery, but immobile in the cephalocaudal axis.

Carotid body tumors develop on both sides of the neck in the same rate, in both females and males. CBT is called as glomus tympanicum, glomus vagal and glomus caroticum when they are located in the tympanic plexus, ganglion nodosus of vagal nerve and the carotid bifurcation, respectively. Although they are rarely seen, CBTs form up most of the head and neck paragangliomas. Due to the pressure exerted on adjacent neural tissues and vessel structures as they develop and due to their malignancy potential, albeit low, they should be removed on detection. They have generally benign characteristic, but they may still transform to malignant tumors in 3% of the cases.² CBTs are rare and form up solely 0.5% of all tumors.³ CBTs are frequently detected as being asymptomatic masses on physical examination in a patient presenting with asymptomatic head or neck mass. Other symptoms include vertigo, pain in the same side as the mass, palpitation, flushing and numbness.⁴ Differential diagnosis includes enlarged lymph nodes, carcinoma metastasis, parotid gland tumors, branchial cleft cysts, neurilemmomas and carotid arterial aneurysms.⁵

Due to their invasion potential to or pressure on adjacent vascular and neural structures, early diagnosis and treatment should be planned. CBTs were surgically classified by Shamblin in 1971.⁶ Surgical treatment is planned according to the classification by Shamblin. First group tumors are those that are small in size, those with little invasion to carotid artery and those that are easy for surgical resection. Second group tumors are those that are larger, and required to be removed carefully due to their minor arterial connections. The third group tumors are those that are large and covering the periphery of carotid artery, requiring a potential arterial resection.

Table-I: Patient classifications.

Shamplin Type1	19
Shamplin Type2	13
Shamplin Type3	3

The first successful operation for CBTs was performed by Maydl in 1886, but the surgery was avoided until 1960's due to mortality rates up to 30%. Following the high mortality rate in a series of operations for carotid paraganglioma by Riegner 1980, it is still of high mortality and morbidity for vessel, neck and brain surgeons.⁷

METHODOLOGY

Thirty five CBTs in 33 patients who were operated between 1999 and 2011 in our hospital were retrospectively examined. Written informed consent was obtained from all the patients. We classified our patients according to Shamblin's classification. Two patients presented with involvement on both sides and the others had single sided involvement. Lesions were on the left side in 20 patients and right side in 15 patients. One patient had been explored surgically in another medical center due to neck mass, and the patient was then referred to our hospital due to uncontrolled bleeding during the operation. The youngest patient was 32, while the oldest was 58 years of age. The mean age was 48, 3.

Twelve of the patients were males, while 21 were females. The most frequent complaint was neck mass. Other complaints included neck pain, vertigo, palpitation, flushing and numbness. The common finding in the physical examination was a rubbery mass which was palpable at a site along the carotid artery trace on the neck under the jaw. Color Doppler USG, CT, MR angiography, and digital subtraction angiography were employed for the diagnosis of the patients (Figure 1 - 2). Accordingly, three patients were evaluated as type 3; 13 as type 2; and 17 as type 1 according to the Shamblin's classification. We

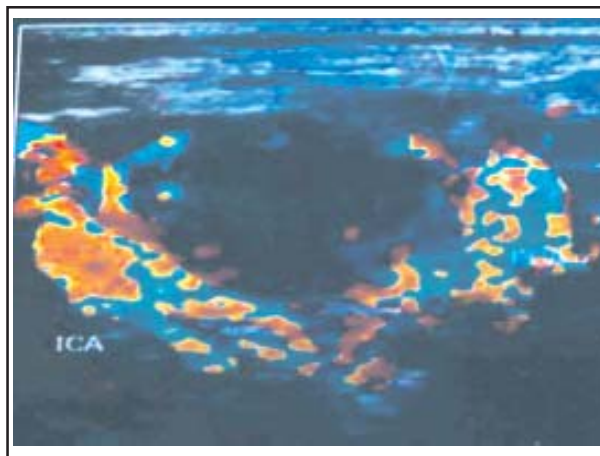


Fig-1: Carotid Color Doppler ultrasound image of one of our patients.

ICA: Internal carotid artery, ECA: External carotid artery.

consider that the methods for early diagnosis have recently increased and become more common.

RESULTS

Due to lung disorders in three of the patients, regional anesthesia was employed as surgical technique, while the others were operated under general anesthesia. We determined the method of anesthesia according to the patient compliance and concomitant diseases in the patients. The patient presenting with lung disorder and compatible with our procedures were exposed to regional anesthesia. An incision of 7 – 8 cm on the same side as the lesion was made between the lower end of the angulus mandibula and 1/3 medial part of the clavicle, parallel to front border of sternokleidomastoid muscle for surgical approach.

After passing through skin and percutaneous tissues, sternokleidomastoid muscle was deviated laterally and main carotid artery and its branches were explored (Figure.3). After revealing the vagal and hypoglossal nerves, they were covered by nylon tapes and set aside the surgical site to avoid any damage. Prior to the removal of the tumor, main carotid artery was controlled by covering internal and external carotid arteries with nylon tapes. In the patients with arterial structures needed to be removed surgically, distal arterial patency was checked. No carotid shunt were employed in any patients during the surgical interventions.

Type 1 patients were subjected to tumoral resection starting from carotid artery bifurcation, without any complication. In two of the type 2 patients, external carotid artery was required to be bound. Bleeding arising from bifurcation was repaired primarily in one patient. Main carotid artery with tumor was excised and external carotid was bound in

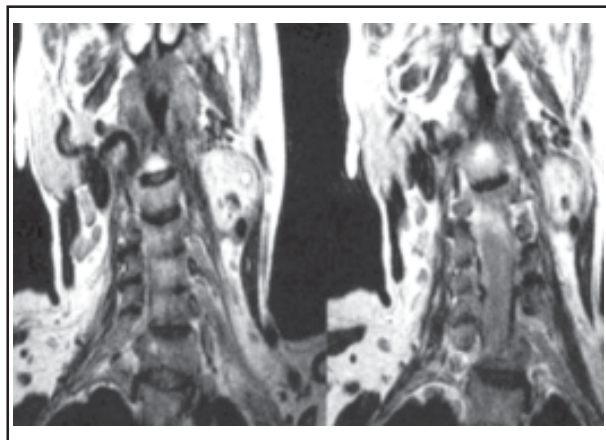


Fig-2: MR image of the neck of one of our patients.

3 patients of type 3 and the patency of the internal carotid artery was provided with PTFE graft interposition in one patient and with saphenous vein graft interposition in two patients. All the tumors resected from the patients were histopathologically examined and all were assessed to be benign CBT lesions. No mortality was seen in any of our patients.

Preoperative and post operative bleeding into the surgical drain was 475ml on average. One of our patients was complicated with postoperative Horner's syndrome. This patient was the one who was referred to our hospital from another medical center following the surgical exploration complicated with external carotid injury. Three patients had hoarseness, but they recovered in the following 6 months. The patients were followed for 6 – 36 months (mean 20 months) postoperatively, with visits every 6 months. No recurrence and distant metastasis were seen during the follow up.

DISCUSSION

CBTs are slowly growing tumors that arise from chemoreceptor tissue in carotid bifurcation. A diffuse mass slowly developing in front of the sternokleidomastoid muscle at the level of hyoid bone on neck should bring that pathology to our minds. The mass may classically be moved laterally, but, as it is adhered to the carotid artery, it cannot be moved medially, which is called Fontaine sign. Murmur may be heard over the mass on auscultation. Although they can be seen at all ages, they generally develop between 30 and 60.⁸ They are more frequently seen

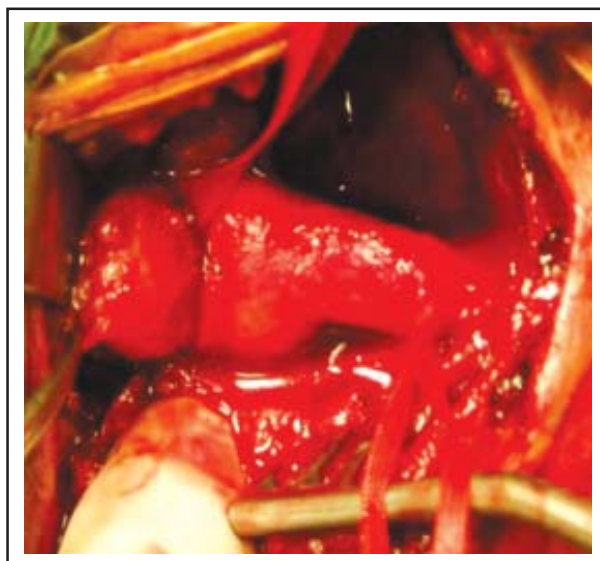

Fig-3: Exploration of the carotid body tumor, image of common carotid artery and its branches during the operation.

Table-II: Complication of surgical treatment.

Mortality	0
Horner syndrome	1
Hoarseness	3
Stroke	0

in females than in males.⁶ 10% of the cases had family history.⁹ The familial form of the disease demonstrates autosomal dominant transition.¹⁰

Although 95% of the sporadic cases presented with one-sided tumor, 30% of those of familial origin had bilateral tumors.¹¹ The underlying reason of CBTs are not clearly known. It is considered that chronic hypoxia can be one of the factors, owing to increased incidence of the disease in patients with chronic obstructive pulmonary disease or in those living in high altitudes. Surveillance, surgical excision, radiotherapy and embolization are frequently used treatment options. Because of their progressive enlargement and pressure associated complications and the fact that they may have malignancy potential, albeit low, treatment based solely on surveillance is not a good option. The most ideal treatment option in case of CBT is surgery. In order to reduce vascularization in CBTs with bleeding risk, coil embolization is advised to perform prior to definitive surgery.⁹

Because of their progressive enlargement and the pressure-related complications they cause to the adjacent structures and the fact that they have malignancy potential, albeit low, surgery at time of diagnosis reduces both mortality and morbidity. Despite mostly being benign, they may show malignant transformation in 3% of the cases.³ 2% - 9% of malignant tumors make metastasis. Due to their slow development in general, they are asymptomatic until reaching a certain size.¹² As the tumor grows dysphagia, odynophagia, dysphonia and pressure signs on 9 and 12 cranial nerves may be seen.^{13,14} When it is considered that the mass is a CBT, USG, technetium (TC) isotope scintigraphy, CT (computerized tomography), magnetic resonance imaging (MRI), MR angiography and if necessary, conventional angiography may be employed in the next stage.

Due to high vascular structure in the tumors, open biopsy should not be applied to any mass suspected to be CBT.¹⁵ Fine needle aspiration biopsy may safely be employed preoperatively.² Treatment selection should be planned by considering the patients' symptoms, age, tumor size, tumor growth rate and complication of surgery. Because of the fact that the tu-

Table-III: Surgical techniques.

Surgical resection	27
Surgical resection+Internal carotid artery division	3
Surgical resection+PTFE greft interpositions	1
Surgical resection+saphen vein greft interpositions	2

mor grows slowly and the fact that it has low malignancy potential and higher risk of vascular problems RT and / or embolization may be preferred as an alternative or as an assistant to surgery.¹⁴ We did not apply RT or preoperative embolization to any of our patients. The bleeding amount in our patients was 475 ml on average and it was in the lower range according to the literature. Except one patient, we did not apply blood transfusion.⁵ Some surgeons suggest the ligation of external carotid artery and its branches in order to reduce the operative complications.¹³

Matticari et al argue that ligation of external carotid artery is not required and they can be protected.¹⁰ (check this reference with list at the end. There is some problem) In our series, external carotid artery of only one patient was required to be ligated. Most of the lesions are benign, and solely 3 - 12.5% of the patients demonstrated malignancy. Malignancy in such tumors is mentioned in case of presence of regional or distant metastasis. Regional lymph ganglia are the locations where the metastasis is most frequently seen.¹⁶ Because stemming from paraganglionic tissues of neural crest origin, CBTs may occur at others sites of the body. Carotid body tumors grow slowly and remain asymptomatic until they reach up to a certain size. The tumor located in front of the sternokleidomastoid muscle at hyoid bone level on the neck grows in time and causes local tension, and exerts pressure on surrounding tissues, thereby leading to regional pain.⁴

Diseases with regional location such as brachial cysts, parotid gland tumor, carotid artery aneurysm, lateral aberrant thyroid gland, malignant lymphoma, neurofibroma, tuberculosis lymphadenitis and metastatic carcinoma should be considered for differential diagnosis prior to the operation. Since carotid artery aneurysm and its elongation in this region is among the differential diagnosis, fine needle aspiration may be very dangerous in the diagnosis of CBT prior to operation.⁹ Invasive or non - invasive tests may be employed in diagnosis; USG, MR angiography and DSA can provide very beneficial data.¹⁷

Color Doppler USG, MR angiography and DSA were preoperatively employed in our cases, which was compatible with the literature.

Postoperative stroke risk in the resection of CBT's with modern surgical techniques is less than 5%.^{18,19} We did not see any stroke in patients in our study. Cranial nerve paralysis rates after operation in the literature are 20 – 40%. Neurological deficit is permanent in 20% of the affected patients.⁴ We observed Horner's syndrome in one of our patients. Postoperative embolization of CBTs may provide complete devascularization.¹⁵ This application is still controversial due to embolic type cerebral ischemia risk. Recent studies have shown that radiotherapy is useful in the treatment of carotid body tumors.¹⁶ Therefore, for regional lymph node metastasis of large, recurrent and malignant CBTs are recommended to be treated with radiotherapy.³

CONCLUSION

CBTs are slowly growing and generally benign tumors arising from chemoreceptor tissues in carotid bifurcation. As CBT grows, it can become inoperable due to possible metastasis or advanced local invasion. Therefore, as soon as the diagnosis is established, surgical intervention should be applied. Surgical results are related to the sizes of tumor tissues, and their adjacency to vascular and neural structures. The tumor should be preferred to be removed surgically in the patients under 50 years of age, who are expected to have long survival.

The surveillance of older patients with multi systematic diseases is more appropriate due to slow growing nature of CBTs. The vascular and neural structures in the tumor and in its periphery should be revealed meticulously during surgical removal, thus preventing them from damage. It should be ensured that distal perfusion is sufficient and arterial structure patency should be secured during clamping period in such cases requiring the removal of vascular structures during clamp.

REFERENCES

- Vogl TJ, Juergens M, Balzer JO, Mack MG, Bergman C, Grevers G et al. Glomus Tumours of the skull base: Combined Use of MR angiography and spin-echo imaging-radiology. 1994;192:103-110.
- Trimas SJ, Mancuso A, de Vries EJ, Cassisi NJ. Avascular carotid body tumor. *Otolaryngol Head Neck Surg* 1994;110(1):131-135.
- Bastounis E, Maltezos C, Pikoulis E, Leppaniemi AK, Klonaris C, Papalambros E. Surgical treatment of carotid body tumours. *Eur J Surg* 1999;165(3):198-202.
- Ilker M, Rabus MB, Kirali K, Yanartas M, Sunar H, Zeybek R, Yakut C. Diagnosis and surgical treatment of carotid body tumors. *Turk Gogus Kalp Cer Damar Derg* 2004;16(2):86-90.
- Sari M, Serin G. M, Özdemir N, Inanlı S, Tutkun A. Carotid Body Tumors treatment modalities. *Kulak Burun Bogaz ve Bas Boyun Cerrahisi Dergisi* 2006;5(3):113-117.
- Shamblin WR, Remine WH, Sheps SG, HARRISON H. G. Carotid Body Tumor (chemodectoma): Clinicopathologic analysis of 90 cases. *Am J Surg* 1971;122:732-739.
- Çicekcioglu F, Iscan Z. H, Kervan U, Mavioglu L, Beyazit M. Carotid Body Tumors Diagnosis and Surgical Approach. *Turkish J Vasc Surg* 2004;13(9):27-32.
- Sevilla García MA, Llo Rente Pendas JL, Rodrigo Tapia JP, Rostan GG, Fente VS, Pelaz AC, et al. Head and neck paragangliomas: Revision of 89 cases in 73 patients. *Acta Otorrinolaringol Esp* 2007;58(3):94-100.
- Isik AC, Erem C, Imamoglu M, Cinel A, Sari A, Maral G. Familial paraganglioma. *Eur Arch Otorhinolaryngol* 2006;263(1):23-31.
- Matticari S, Credi G, Pratesi C, Bertini D. Diagnosis and surgical treatment of the carotid body tumors. *J Cardiovasc Surg (Torino)* 1995;36(3):233-239.
- Muhm M, Polterauer P, Gstottner W, Temmel, Richling B, Undt G, et al. Diagnostic and therapeutic approaches to carotid tumors in inhabitants of altitudes higher than 2000 meters carotid body tumors. Review of 24 patients *Arch Surg* 1997;132(3): 279-284.
- Rodriguez-Cuevas S, Lopez-Garza J, Labastida-Almendaro S. Carotid above sea level. *Head Neck* 1998;20(5):374-378.
- Netterville JL, Reilly KM, Robertson D, Reiber ME, Armstrong WB, Childs P. Carotid body tumors: A review of 30 patients with 46 tumors. *Laryngoscope* 1995;105:115-126.
- Der Mey AG, Jansen JC, van Baalen JM. Management of Carotid Body Tumors. *Otolaryngol Clin North Am* 2001;34(5):907-924.
- Kunt A, Bulut F, Demir CS. Carotid Body Tumors. *Turk Gogus Kalp Damar Cer Derg* 2003;11:198-200.
- Kadioglu HH, Sengul G, Aydin IH. Carotid Body Tumors: Turkey Klinikleri *J Surg Med Sci* 2006;2:166-168.
- Aydogan H, Orhan G, Aykut-Aka S, Albeyoglu S, Yucel O, Sargin M, et al. Carotid Body Tumors. *Asian Cardiovasc Thorac Ann* 2002;10:173-175.
- Kawada T, Oki A, Iyano K, Bitou A, Okada Y, Matsuo Y, et al. Surgical treatment of atherosclerotic and dysplastic aneurysms of the extracranial internal carotid artery. *Ann Thorac Cardiovasc Surg* 2002;8:183-187.
- Basel H, Odabasi D, Hazar A, Ekim H. Carotid Body Tumors Diagnosis and Surgical Approach. *Cardiovascular Sci* 2009;21:1:13-18.

Authors:

- Halil Basel, MD, Department of Cardiovascular Surgery, Bezmi Alem Vakif University, Turkey.
- Hasan Ozturk, MD, Department of Radiology, Van Yuksek Ihtisas Hospital, Turkey.
- Cemalettin Aydin, MD, Department of Cardiovascular Surgery, Bezmi Alem Vakif University, Turkey.
- Cemil Goya, MD, Department of Radiology, Medical Park Hospital, Turkey.
- Ekrem Bayar, MD, Department of Cardiovascular Surgery, Medical Park Hospital, Turkey.