

Impact of depressed skull fracture surgery on outcome of head injury patients

Shakeel Ahmad¹, Ali Afzal²,
Lal Rehman³, Farrukh Javed⁴

ABSTRACT

Objective: To assess outcomes in surgically managed patients with depressed skull fractures and associated moderate to severe head injury.

Methods: The study was conducted in the Department of Neurosurgery Jinnah Postgraduate Medical Centre, Karachi, from January 2016 to December 2017. We analyzed 90 patients with depressed skull fracture managed surgically from January 2015 to December 2016. The patients selected for this study belonged to all age groups with clinically palpable depressed skull fracture confirmed by CT brain with bone window. Outcome was assessed by Glasgow outcome score.

Results: Total 90 patients were included in the study. Sixty (66.7%) were male and 30 (33.3%) were female with mean age of years 27.58+11.329. Among 90 patients, 38.8% were aged between 21 and 30 years. Road traffic accident was seen in 72 (80%) patients. The commonest site of fracture was frontal region in 50 patients (55.6%). GCS improved post operatively on comparison to preoperative. Five patients expired.

Conclusion: Depressed skull fracture is common neuro surgical issue. Timely surgical management gives excellent results by decreasing morbidity and mortality.

KEYWORDS: Depressed skull fracture, Head injury, Glasgow Outcome Scale.

doi: <https://doi.org/10.12669/pjms.341.13184>

How to cite this:

Ahmad S, Afzal A, Rehman L, Javed F. Impact of depressed skull fracture surgery on outcome of head injury patients. *Pak J Med Sci.* 2018;34(1):130-134. doi: <https://doi.org/10.12669/pjms.341.13184>

This is an Open Access article distributed under the terms of the Creative Commons Attribution License (<http://creativecommons.org/licenses/by/3.0>), which permits unrestricted use, distribution, and reproduction in any medium, provided the original work is properly cited.

INTRODUCTION

Incidence of trauma increased both in developing and developed countries especially in congested cities because of high traffic flow. This makes it

a worldwide health and social issue.¹ Traumatic head injury is a serious issue around the world.^{2,3} In majority of head injury cases, the incidence of depressed skull fracture is increasing, requiring trained staff and modern equipments for better care to save the lives of the patients.⁴ The patients are victims of road traffic accidents, assaults or other high-energy collisions.⁵ The introduction of Advanced Trauma Life Support (ATLS) training program, helped in better understanding of management of head injury patients.⁶ Depressed skull fracture usually occurs following high-speed impact with a small object. The outer and inner tables of skull typically break concurrently.⁷ Depressed skull fracture over superior sagittal sinus (SSS) is the commonest type of dural venous sinus injury with significant morbidity and mortality. Significant dural sinus injury occurs in 1.5 to 5% of all head injury cases.⁸ Compound depressed fractures are surgical emergencies which should

1. Dr. Shakeel Ahmad, MBBS.

2. Dr. Ali Afzal, MBBS.

3. Dr. Lal Rehman, FCPS.

4. Dr. Farrukh Javed, MBBS.

1-4: Department of Neurosurgery,
Jinnah Postgraduate Medical Center,
Karachi, Pakistan.

Correspondence:

Dr. Farrukh Javed, MBBS,
Senior Resident,
Department of Neurosurgery,
Jinnah Postgraduate Medical Center,
Rafiqi Shaheed Road, Karachi, Pakistan.
Email: farrukhjavedkhi@gmail.com

* Received for Publication: May 22, 2017

* Revision Received: January 11, 2018

* Revision Accepted: January 15, 2018

be treated promptly. Early definitive diagnosis and management of skull fracture decreases morbidity and mortality.⁹ The aim of this study was to develop a plan for better surgical management of depressed skull fracture.

METHODS

The study was conducted in the Department of Neurosurgery Jinnah Postgraduate Medical Centre, Karachi, from January 2016 to December 2017, with approval of Institutional Review Board. A total of 90 patients with depressed fractures with and without associated polytrauma were selected for this study belonging to all age groups. These had moderate to severe head injury as defined by GCS <12 and also included seven case of polytrauma. Pregnant patients, patients having previous history of head injury, and patients with head injury associated with systemic disease such as diabetes and hypertension were excluded. All polytrauma patients had long bone fractures or rib fractures and were managed conservatively. All information's were recorded in proforma. In all cases, X-Ray skull and CT brain with bone window was done to confirm the site of skull fracture. All patients in the study were managed operatively. Surgical modalities include elevation of closed as well as open depressed fracture, dural repair was done for dural tear and drainage of extradural hematoma or subdural hematoma. Outcome of surgical management was assessed by Glasgow outcome score. The patients were also examined for complications (neurological deficit, CSF leak, wound infection, death). The patients were discharged after 5–15 days, depending on the

severity of head injury. Follow-up of all patients was carried out for three month to study the outcome of surgical management and complications.

Data was analyzed using SPSS version 22. All the data was expressed as mean \pm SD (standard deviation) and percentage (%), as appropriate. The statistical significance of differences between the values was assessed by Chi-square test and p-value of < 0.05 was considered statistically significant.

RESULTS

Total 90 patients of depressed skull fracture were enrolled in the study. Sixty patients (66.7%) were male and 30(33.3%) were female with mean age of years 27.58 \pm 11.329. Of 90 patients, 28(31%) were aged below 20 years. The peak incidence was observed in patients belonging to 21–30 age groups. The commonest cause of depressed skull fracture was road traffic accident, seen in 72 (80%) patients; whereas in 12 (13.3%), mode of injury was fall from height and in 6 (6.7%) fall of object on patient. All patients presented with the main complaint of altered level of conscious followed by vomiting and fit as shown in Table-I.

The commonest site of fracture was frontal region seen in 50 cases (55.6%) as shown in Table-II. Compound fracture of skull was found in 70 cases (77.7%) whereas simple fracture was found in 20 cases (22.3%). Dura was intact in 46 cases (51.1%), but was breached in 44 cases (48.9%). Associated brain injuries like extradural hematoma was reported in ten patients (11.1%), subdural hematoma in five patients (5.6%), involvement of venous sinuses in 5 cases (5.6%) and brain

Table-I: Age and sex distribution, mode of injury and mode of presentation.

	Characteristics	Frequency	Percentage	Mean \pm SD
Age (years)	0-10	2	2.2	27.58 \pm 11.329
	11-20	26	28.8	
	21-30	35	38.8	
	31-40	13	14.4	
	41-50	9	10	
	51-55	5	5.8	
Sex	Male	60	66.7	
	Female	30	33.3	
Mode of Injury	Road traffic accident	72	80	
	Fall from height	12	13.3	
	Fall of object on patient	6	6.7	
Mode of presentation	Altered level of Consciousness	90	100	
	Vomiting	14	15.6	
	Fits	13	14.4	
	ENT bleeding	7	7.8	

Table-II: Sites of fracture and type of fractures distribution.

Characteristics		Frequency	Percentage	P-value	
Sites of fracture	Frontal	50	55.6	0.181	
	Parietal	14	15.6		
	Temporal	11	12.2		
	Occipital	15	16.7		
Type of fractures	Open fracture	Dural tear	40	44.4	0.061
		Dural intact	30	33.3	
		Total	70	77.7	
	Closed fracture	Dural tear	4	4.4	0.998
		Dural intact	16	17.8	
		Total	20	22.2	

Table-III: Associated brain injuries.

Characteristics		Frequency	Percentage	P-value	
Associated Brain injuries	Intracranial hematoma	EDH	10	11.2	0.000
		SDH	5	5.6	
	Involvement of venous sinus	5	5.6		
	Brain contusions	35	38.8		

contusions in 35 cases (38.8%). Preoperatively, there were 70 patients (66.7%) with moderate head injury (GCS:8-12) and 20 patients(33.3%) were with severe head injury (GCS<8). All patients underwent surgery and in all cases, antibiotics and antiepileptics were given. Postoperatively outcome was assessed by Glasgow outcome score as shown in Fig.1. Complication occurred in 16 patients, 4 patients (4.4%) had neurological deficit, four (4.4%) patients had wound infection, three patients (3.3%) had CSF leak and five patients (5.6%) expired.

DISCUSSION

Trauma is a major problem both in the developed and developing countries. Head injury is a major risk factor responsible for mortality in young population.¹⁰ We analyzed 90 cases of depressed

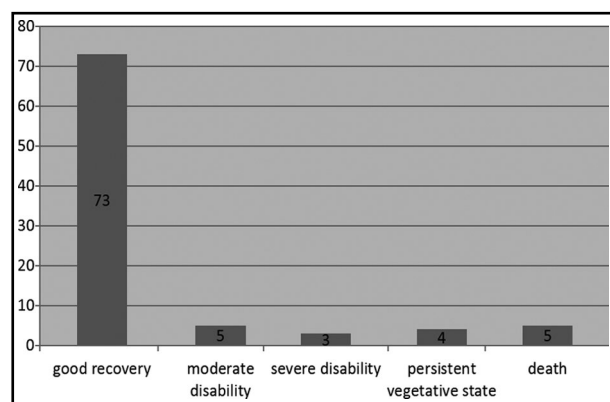


Fig.1: Glasgow outcome score.

skull fractures treated in context of mode of injury, mode of presentation, site of fracture, type of fracture, associated brain injuries, surgical management and outcome of patients. Various aspects were compared with similar work and studies carried out in the past.

In a depressed skull fracture, the major bone depression can occur at the interface of fracture. Majority of depressed skull fractures occur over frontoparietal region as bone is comparatively thin and prone to trauma.¹¹ Surgical elevation is the standard treatment of depressed skull fractures if depression is equal or more than thickness of normal adjacent skull.¹² Surgical elevation of depressed skull fractures over a venous sinus may cause fatal hemorrhage if a depressed fragment has been plugging a sinus tear.¹³ The surgical treatment for depressed skull fractures located over major venous sinuses is controversial. However surgical decompression is indicated if sinus obliteration and related intracranial hypertension are present clinically and radiologically.^{14,15} Early surgical management on a compound depressed skull fracture over the superior sagittal sinus with epidural hematoma may give a better outcome.¹⁶

As regards the mode of trauma, assault was the commonest cause found by Hossain et al.¹⁷ and Al-Haddad and Kirillos¹⁰ whereas in the study by Ali et al.¹ fall from height was the main cause of injury (51.94%). In Rolekar et al.⁶ study, road traffic accident was the main cause of injury (60%).

Ozer FD et al. reported road traffic accident as the commonest cause of depressed skull fracture followed by assault.¹⁸ In a study by Braakman¹⁹ fifty one percent of the patients had road traffic accident followed by fall from height in 26% patients. In our study, road traffic accident was the main cause of injury (80%) that is most probably because of not following traffic rules consistently.

As for as the presentation of depressed skull fracture is concerned, it presents with loss of consciousness, fits, vomiting and ENT bleed. In Rolekar et al.⁶ study, the most frequent cause of presentation was unconsciousness (56%) followed by ENT bleeding (34%), whereas in Ali et al.¹ and Hossain et al.¹⁷ studies it was unconsciousness in 40% and 25% cases, respectively. In our study, the most common mode of presentation was altered level of consciousness (100%) followed by vomiting (15.6%), fits (14.4%) and ENT bleeding (7.8%).

Skull fractures can occur at any site of skull depending upon the mode they are caused. In Rolekaretal⁶ study the frontal region was the most common site of injury in 52% patients. In Ali's et al. Study¹, parietal was the most common site of injury followed by temporal region. In studies by Braakman¹⁹ and Mehdi et al.²⁰, frontal region was the commonest site of fracture in accident. In our study frontal region was the most common site of injury in 55.6% patients followed by occipital in 16.7%, parietal in 15.6% and temporal in 12.2% cases.

In Rolekar et al.⁶ study 68% of the fractures were compound fractures. However, in studies by Ali et al.¹ Braakman¹⁹, Hossain et al.¹⁷ compound fractures were found in 73.5%, 86%, and 43.64% patients, respectively. In our study, 77.7% were open fractures while 22.2% of the fractures were closed fractures.

In depressed skull fractures, dura is breached in considerable number of cases as has been reported by different studies. In Hossain et al. study¹⁷ of 93 patients, 67 patients were operated with 17 patients (25%) having dural tears. In Braakman¹⁹ study of 225 patients, 44% had dura tear. In our study, 48.9% patients had dural tear which is comparable to Braakman study.¹⁹

Most often depressed skull fractures are associated with underlying hematoma, contusion and venous sinus involvement which might be much dangerous for patients as compared to fracture alone. In Mehdi et al. study,²⁰ 31 patients had brain contusion and four had SDH. In Hossain et al. study,¹⁷ 22% patients had EDH and 31% had brain contusion. In

Ali et al. study¹, 10.78% patients had ICH and 3.9% had involvement of venous sinus. In our study, 35(38.8%) patients had brain contusions; 10(11.2%) patients had extradural hematoma and five(5.6%) patients had subdural hematoma and five(5.6%) patients had involvement of venous sinuses.

Prompt diagnosis and management of skull fracture reduces morbidity and mortality as well as help in restoring maximal functional and aesthetic rehabilitation. We saw good recovery in 73(81.1%) patients and moderate disability in five(5.5%) patients similar to findings of Rolekar⁶ and Al-Haddad and Kirollos¹⁰ which shows intervention in even in moderate to severe head injury can be beneficial. Surgical interventions are done to benefit the patients, but complications can also occur as reported by different studies. In Rolekar et al. study⁶ postoperative infection was found in 16.66% cases, 8% patients had neurological deficit like hemiparesis whereas in the study by Al-Haddad and Kirollos¹⁰ 12.3% patient had episodes of postoperative epilepsy. In our study complications occurred in sixteen patients, four patients (4.4%) had neurological deficit, four patients (4.4%) had wound infection, three patients (3.3%) had CSF leak and five patients (5.6%) expired.

CONCLUSION

Patients with moderate to severe head injury can be fatal if not managed timely. Depressed fracture if not managed, may affect the outcome as well in these patients. Surgery for depressed fracture should be done because early diagnosis and management of depressed skull fracture decreases morbidity and mortality.

Grant Support & Financial Disclosures: None.

REFERENCES

1. Ali M, Ali L, Roghani IS. Surgical management of depressed skull fracture. *JPMI* 2003;17(1):116-123. URL: <http://www.jpms.org.pk/index.php/jpms/article/view/812>
2. Yuan Q, Liu H, Wu X, Sun Y, Yao H, Zhou L, et al. Characteristics of acute treatment costs of traumatic brain injury in Eastern China--a multi-centre prospective observational study. *Injury*. 2012;43(12):2094-2099. doi: 10.1016/j.injury.2012.03.028.
3. Perez K, Novoa AM, Santamarina-Rubio E, Narvaez Y, Arrufat V, Borrell C, et al. Incidence trends of traumatic spinal cord injury and traumatic brain injury in Spain, 2000-2009. *Accid Anal Prev*. 2012;46:37-44. doi: 10.1016/j.aap.2011.12.004.
4. Choi BY, Jang BG, Kim JH, Lee BE, Sohn M, Song HK, et al. Prevention of traumatic brain injury-induced neuronal death by inhibition of NADPH oxidase activation. *Brain Res*. 2012;1481:49-58. doi: 10.1016/j.brainres.2012.08.032.

5. Foreman PM, Harrigan MR. Blunt Traumatic Extracranial Cerebrovascular Injury and Ischemic Stroke. *Cerebrovasc Dis Extra*. 2017;7(1):72-83. doi: 10.1159/000455391.
6. Rolekar NG. Prospective study of outcome of depressed skull fracture and its management. *Int J Medical Sci Public Health*. 2014;3(12):1540-1545. doi: 10.5455/ijmsph.2014.271020141.
7. Miyake S, Yamamura K, Abe H. A Case of Depressed Skull Fracture Involving only the Inner Table. *No shinkei Geka. Neurol Surg*. 2016;44(7):599-603. doi: 10.11477/mf.1436203337.
8. Tripathi AK, Kansal S, Murthy K, Kumar A, Baid A. Is the Elevation of Depressed Calveria over Superior Sagittal Sinus (SSS)-(No Men Land) Rightly Contraindicated? *Ind J Anat Sur Head Neck Brain*. 2016;2(1):32-34.
9. Fitzsimmons-Francis C, Morris P. Prehospital care: Triage and trauma scoring. *Surg Int*. 2001;52:25.
10. Al-Haddad SA, Kirolos R. A 5 year study of the outcome of surgically treated depressed Skull fractures. *Ann R Coll Surg Engl*. 2002;84:196-200.
11. Nazer H Qureshi. (Jul 18, 2017). Skull Fracture. *Medscape*. Retrieved 11/12011 from <https://emedicine.medscape.com/article/248108>.
12. Kim YJ, Lee SK, Cho MK, Kim YJ. Elevation of Depressed Skull Fracture with a Cup of Breast Pump and a Suction Generator: A Case Report in Technical Aspects. *J Korean Neurosurg Soc*. 2007;42(4):346-348.
13. Geisler FH, Rodrigues E, Manson PN. Traumatic Skull and Facial Fractures. In: *Principles of Neurological Surgery* 3rd edition. Philadelphia, Elsevier Saunders. 2012;365-369.
14. Uzan M, Ciplak N, Dashti SG, Bozkus H, Erdinçler P, Akman C. Depressed skull fracture overlying the superior sagittal sinus as a cause of benign intracranial hypertension. Case report. *J Neurosurg*. 1998;88(3):598-600.
15. Meltzer H, LoSasso B, Sobo EJ. Depressed occipital skull fracture with associated sagittal sinus occlusion. *J Trauma*. 2000;49(5):981.
16. Sendjaja AN, Sutiono AB, Faried A, Arifin MZ. Open Depressed and Compound Elevated Skull Fracture over the Superior Sagittal Sinus: A Case Report. *J Surg*. 2016;2968(001). doi: 10.17352/2455.
17. Hossain MZ, Mondle MS, Hoque MM. Depressed skull fracture: outcome of surgical treatment. *J Teachers Assoc* 2008;21:140-46..
18. Ozer FD, Yurt A, Sucu HK, Tektas S. Depressed fractures over cranial venous sinus. *J Emerg Med*. 2005;29(2):137-139.
19. Braakman R. Depressed skull fracture: data, treatment and follow-up in 225 consecutive cases. *J Neural Neurosurg Psychiatry*. 1972;35:395-402
20. Mehdi SA, Ahmed CB, Dogar H, Shaikat A. Depressed skull fracture: Interrelationship between CT evaluation of & its clinical findings. *Professional Med J*. 2010;17:616-622.

Authors` Contribution:

SA conceived and designed the study.
AA did statistical analysis & editing of manuscript.
LR did review and final approval of manuscript.
FJ did data collection and manuscript writing.