

Successful localization and removal of two ingested sewing needles: One migrated into the liver and the other stuck in the ascenden colon

Akin Aydogan¹, Orhan Veli Ozkan², Ibrahim Yetim³, Ersan Semerci⁴,
Elmir Bayramoglu⁵, Ahmet Aslan⁶, Muhyittin Temiz⁷

ABSTRACT

Ingested foreign bodies are mostly spontaneously passed out in the feces. However sharp, long, solid foreign bodies such as sewing needles could cause life-threatening complications. We report a 34 years old female patient with history of two sewing needle ingestion eight years ago. Radiologic images revealed that one of the needles had immigrated to the liver, one impacted the ascenden colon. They were removed via laparotomy with a successful preoperative localization. Foreign bodies which can't be self-extruded and unremoved via laparoendoscopy should be removed with laparotomy after proper localization since they could cause life-threatening complications.

KEY WORDS: Ingested Sewing Needle, Localization, Surgical removal.

Pak J Med Sci October - December 2011 Vol. 27 No. 5 1187-1190

How to cite this article:

Aydogan A, Ozkan OV, Yetim I, Semerci E, Bayramoglu E, Aslan A, et al. Successful localization and removal of two ingested sewing needles: One migrated into the liver and the other stuck in the ascenden colon. Pak J Med Sci 2011;27(5):1187-1190

INTRODUCTION

Most ingested foreign bodies usually pass out in the feces uneventfully.¹ However sharp, thin, long,

stiff foreign bodies such as sewing needles, tooth-picks and nails are dangerous since they may cause fatal complications such as intestinal perforation,² bleeding, abscess,³ obstruction⁴ and migration to the pancreas or liver.⁵ Sharp foreign bodies account for a minority of the ingested foreign bodies because of their shape and are usually presented with patients who have psychologic disorders⁶, suicidals or prisoners. These foreign bodies cause perforation and following complications more frequently than other foreign bodies. Perforation in these cases may cause following complications such as bleeding, peritonitis, abscess, internal or external fistula formation or the foreign body can migrate to another organ silently.⁷ Most of the patients don't give a true medical history, do not remember when or how the ingestion happened because of their mental status. So a precious medical history which would provide an easy diagnosis is not usually available in these cases.

In the present case we describe the management of two ingested sewing needles; one migrated to the liver, one impacted the ascenden colon.

1. Akin Aydogan,
2. Orhan Veli Ozkan,
3. Ibrahim Yetim,
4. Ersan Semerci,
Tos State Hospital,
Mersin, Turkey.
5. Elmir Bayramoglu,
Adiyaman University, Faculty of Medicine,
Department of General Surgery,
Adiyaman, Turkey.
6. Ahmet Aslan,
7. Muhyittin Temiz,
- 1-3,6,7: Mustafa Kemal University, Faculty of Medicine,
Department of General Surgery,
Hatay, Turkey.

Correspondence:

Akin Aydogan,
Assistant Professor of General Surgery,
Mustafa Kemal University, Faculty of Medicine,
Department of General Surgery,
31100 Hatay, Turkey.
E-Mail: drakinay@yahoo.com

- * Received for Publication: July 1, 2011
- * Revision Received: August 3, 2011
- * Revision Accepted: October 20, 2011

CASE REPORT

A 34 year old female was admitted to the emergency department with abdominal pain presenting for a month which became stronger in the last two days. She claimed that she might have swallowed sewing needles eight years ago. There was no pathology in psychiatric consultation of the patient. On her physical examination there was tenderness on the right lower abdominal area. Signs of peritoneal irritation like rebound or guarding were not present.

Abdominal X-ray revealed two sewing needles; one in the epigastric area and one on the right lower area (Figure.1-A). Abdominal ultrasonography [Siemens Acuson Antares 5.0, Germany] showed that one of the needles was in the liver parenchyme (Figure.1-D). Non contrast abdominal tomography at 1cm cuts was performed to determine the precise localisation of the needles. Tomography [Shimadzu SCT 7800 TC, Kyoto, Japan] determined that one of the needles was migrated to the left lobe (Figure.1-B) of the liver and the other impacted the middle part of the ascending colon (Figure.1-C). Direct abdominal graphy which was performed after five days revealed that the position of the needles wasn't changed. Because it was thought that needles wouldn't be self-extruded colonoscopy was tried. But the patient couldn't tolerate. Control abdominal graph revealed that needles were in the same position.

Surgical procedure: At the next step laparoscopy was planned and was performed under general anesthesia. However needles could not be seen with laparoscopy so the operation was converted to laparotomy. Before the incision; perioperative scopy revealed that the needle which was stuck in the ascenden colon was still there (Figure.1-E). Since there was a long distance between the needle in colon and the one in the liver, a small incision from the right lower quadrant was thought to be helpful to remove the needle in the colon.

We gained access to abdominal cavity with transrectal incision and the needle was detected with palpation. Since the direction of the needle was determined with scopy and palpation, the needle was removed without performing a colotomy. The needle was palpated and pressed with the first and second phalanges of the right hand. Then it was pulled out from the sharp side and was removed by perforating the colon wall. The exit area of the needle was repaired with seromuscular suturation with 3/0 silk. After the incision was repaired, a

median incision was performed. The needle was detected in the left lobe of the liver with palpation. A surgical clamp was attached to the capsule and scopy was performed to determine the route for the needle. After orientation, the capsule was cut with electrocotherisation and the needle was found approximately in 2.5cm depth in the parenchyme. Because of corrosion, the needle was broken into two pieces during removal the liver was sutured (Figure.1-F). Incisions were closed after placing silicon drains into right paracolic and subhepatic regions. The patient was discharged on postoperative sixth day with no complications. The three months follow up was uneventful.

DISCUSSION

Majority of ingested foreign bodies entering the stomach pass through the gastrointestinal tract without any side effect.¹ Experimental studies with sharp foreign bodies revealed that tip of the foreign material touches the wall of intestine and cause the intestine to be dilated. Based on that it was concluded that foreign bodies are extruded by peristaltic movements.⁸ However long, sharp and narrow foreign bodies which are not digested can be stuck more frequently and cause perforation, bleeding, ileus. Rarely they can migrate to the liver, omentum, mesentery or anterior abdominal wall. Since it is a rare condition for a foreign body to remain in the body and to migrate, case reports are more common than large series in the literature. Therefore we also report a case about the management of two sewing needles which migrated to liver and colon after being ingested.

Foreign objects that were not defecated, may be detected by proper anamnesis from both the patient and relatives and test results. In addition, foreign body ingestion may cause no complaints or give symptoms of complications. The foreign bodies, which cause no symptoms initially, could later migrate different regions such as liver, omentum, pancreas and anterior abdominal wall. In our patient, patient had abdominal pain after 8 years of ingestion. One needle had migrated the liver and the other had been fixed to ascending colon.

A detailed medical history is very important in these cases and facilitates the diagnosis. However children and patients with mental disorders will not give an accurate history. The localisation of the foreign bodies is easily determined if they are apparent in X-ray but it might be difficult to localise foreign bodies such as tooth picks which are made

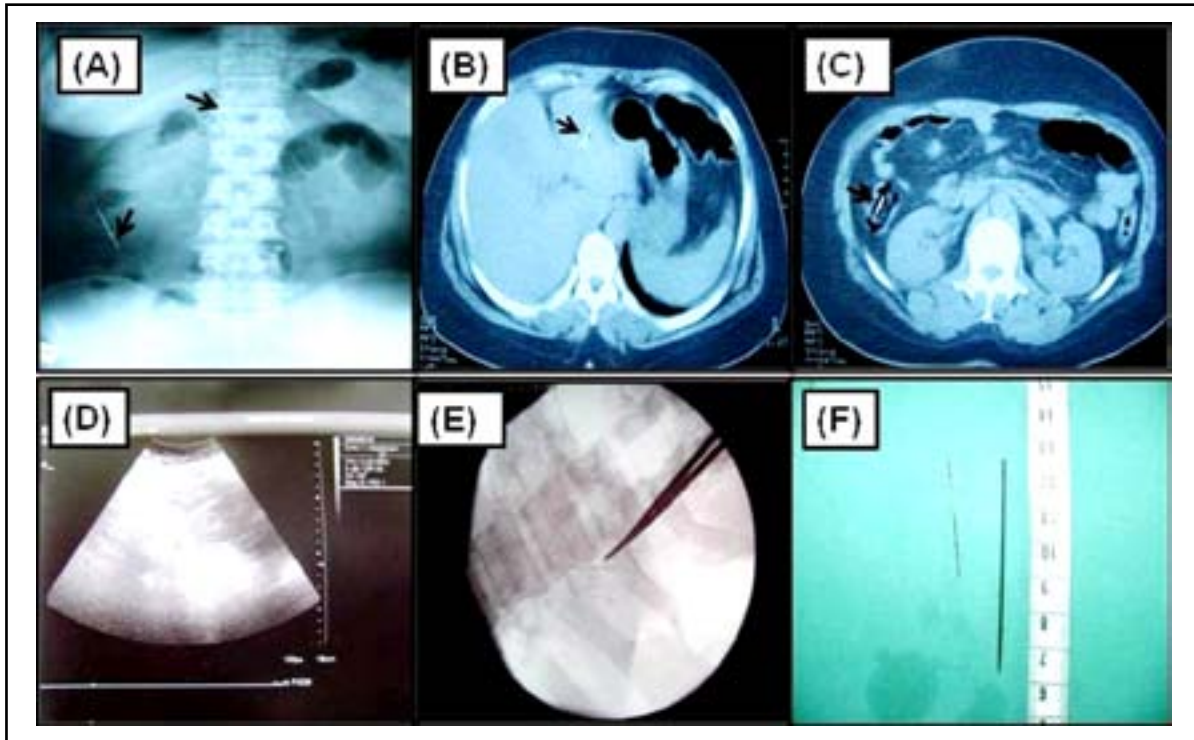


Figure.1-A: Two sewing needles on Plain abdominal radiograph.

Figure.1-B: One of the needles was seen on computed tomogram of the abdomen on the liver left lobe.

Figure.1-C: The view of the other needle in the middle colon on computed tomogram.

Figure.1-D: The view of the needle in liver left lobe on ultrasonography.

Figure.1-E: Intraoperative scopic view of the needle in liver left lobe.

Figure.1-F: Removed sewing needles.

of wood with X-ray and endoscopy or laparotomy can be required for a definite diagnosis.

The management of foreign bodies depends on the age of the patient, clinical condition, the size, shape, type of foreign body, the anatomical location and the endoscopic technical ability of the unit.⁵ Most ingested foreign bodies are expected to pass through the gastrointestinal tract and eventually pass out in the stool.² Impacted foreign bodies almost always require intervention. Sharp, narrow, long foreign bodies are suggested to be removed by endoscopic or laparoscopic means.⁹ Operative management is less considered as the endoscopic techniques improve but it is still the only choice of treatment in some cases. Endoscopic removal of the foreign body is the first choice of interventional treatment but can be associated with serious morbidity and mortality.¹

Long, spicular, indigestible, sharp foreign objects should be closely followed if it was not defecated itself. Foreign body which was not defecated during control, the localization should be monitored by

radiograph. In case sharp and spicular foreign bodies couldn't be extruded after three or five days, they may cause serious complications. Therefore there are studies advocating the necessity of endoscopic or laparoscopic removal.⁹ Objects that can not be removed by the help of these methods, are removed by laparotomy with point localization of the object by using intraoperative roentgenoscopy¹⁰ after detecting its localization via direct abdominal X-ray, computed tomography and ultrasonography. Because the localization may change just before the operation, repetition of direct abdominal radiograph is recommended. In our patient, the localization of the needles was determined in the preoperative period by direct abdominal radiograph, abdominal CT and ultrasound. First, the needle was tried to be remove from the colon by colonoscopy. However, the patient was unable to tolerate the procedure successfully. Therefore laparotomy was planned after detecting that needle position didn't change. Foreign objects were removed from stomach, small intestine and colon by

opening the wall of those organs. As in our case, slim-spicular needles may be removed less invasively without applying enterotomy or colotomy by piercing through the wall of hollow organs at the direction of the tip of sharp needle.

Foreign bodies in the liver can be removed laparoscopically. However, deeply localised and rusted foreign bodies as seen in our case should be removed from the liver by laparotomy. In our case, the needle was broken into two pieces during removal with forceps because of corrosion.

CONCLUSIONS

In conclusion if sharp and spicular foreign objects don't pass out spontaneously, it should be removed by endoscopic and laparoscopic methods. Laparotomy is necessary when the object couldn't be reached with these methods. Before the intervention, determining the localization by radiography, tomography and ultrasound increases the rate of success. Localization needs to be evaluated with scopy during operation.

REFERENCES

1. Zhang S, Cui Y, Gong X, Gu F, Chen M, Zhong B. Endoscopic management of foreign bodies in the upper gastrointestinal tract in South China: a retrospective study of 561 cases. *Dig Dis Sci* 2010;55:1305-12
2. Hsu SD, Chan DC, Liu YC. Small-bowel perforation caused by fish bone. *World J Gastroenterol* 2005;28:1884-5.
3. Chiang TH, Liu KL, Lee YC, Chiu HM, Lin JT, Wang HP. Sonographic diagnosis of a toothpick traversing the duodenum and penetrating into the liver. *J Clin Ultrasound* 2006;34:237-40.
4. Tai AW, Sodickson A. Foreign body ingestion of blister pill pack causing small bowel obstruction. *Emerg Radiol* 2007;14:105-8.
5. Lanitis S, Filippakis G, Christophides T, Papaconstandinou T, Karaliotas C. Combined laparoscopic and endoscopic approach for the management of two ingested sewing needles: one migrated into the liver and one stuck in the duodenum. *J Laparoendosc Adv Surg Tech A* 2007;17:311-4.
6. Carp L. Foreign bodies in the gastrointestinal tracts of psychotic patients. *Arch Surg* 1950;60:1055-75.
7. Hashmonai M, Kaufman T, Schramek A. Silent perforations of the stomach and duodenum by needles. *Arch Surg* 1978;113:1406-9.
8. Ozkan Z. Effectiveness of single-dose sodium phosphate enema through stool removal of ingested foreign bodies Yutulan yabancı cisimlerin gaita ile çıkarılmasında tek dozluk sodyum fosfat enemanın etkinliği. (In Turkish) (Expert thesis). 2004 Available from: http://www.istanbulsaglik.gov.tr/w/tez/pdf/genel_cerrahi/dr_zeynep_ozkan.pdf.
9. Bulbuloglu E, Yuksel M, Kantarceken B, Kale IT. Laparoscopic removal of a swallowed sewing needle that migrated into the greater omentum without clinical evidence. *J Laparoendosc Adv Surg Tech A* 2005;15:66-9.
10. Ma CJ, Jan CM, Hsieh JS, Huang YS, Wang WM, Chan HM, et al. Successful localization and surgical removal of ingested sewing needles under mini C-arm fluoroscopy: a case report. *Kaohsiung J Med Sci* 2006;22:457-60.

Authors Contribution:

Collection of Data: Ersan Semerci, Elmir Bayramoglu, Ibrahim Yetim

Acquisition of Data: Akin Aydogan, Muhyittin Temiz, Ersan Semerci

Interpretation of Data: Akin Aydogan, Ahmet Arslan, Muhyittin Temiz, Elmir Bayramoglu, Ibrahim Yetim

Conception and Design: Akin Aydogan, Ersan Semerci, Ahmet Arslan

Drafting the Article: Akin Aydogan, Muhyittin Temiz, Ibrahim Yetim