

## A case of sirenomelia sequence

Mevlit Ikbali<sup>1</sup>, Hasan Kahveci<sup>2</sup>, Basak Adakli Aksoy<sup>3</sup>,  
Fuat Laloglu<sup>4</sup>, Ebru Kacmaz<sup>5</sup>, Muhammed Yunus Alp<sup>6</sup>

### ABSTRACT

Sirenomelia sequence is a rare congenital anomaly. This is also known as “mermaid syndrome” because of typical feature of lower limb. Sirenomelia sequence is characterized with a single midline lower limb. Our case was an infant delivered at 34 gestational weeks by spontaneous vaginal delivery from a 34 years old gravida 2, para 0. Parents are not relative. Infant has one femur, one tibia and one phalanx at lower extremity. Calcaneus, metatarsals and other bones of the foot are absent. Patient has anal atresia and renal agenesis. Determination of sex was impossible since external genitalia was absent. Although some risk factors (e.g. maternal diabetes) have been suggested, etiology of sirenomelia sequence is debated. In this report, we describe a premature infant with sirenomelia sequence because of very rare presentation.

**KEY WORDS:** Sirenomelia sequence, Congenital abnormalities.

Pak J Med Sci October - December 2012 Vol. 28 No. 5 968-970

### How to cite this article:

Ikbali M, Kahveci H, Aksoy BA, Laloglu F, Kacmaz E, Alp MY. A case of sirenomelia sequence. Pak J Med Sci 2012;28(5):968-970

### INTRODUCTION

Sirenomelia sequence is a rare congenital malformation characterized with a single midline lower limb.<sup>1</sup> Incidence of sirenomelia sequence is between 1/60.000 and 1/100.000.<sup>2,3</sup> Other anomalies associated with sirenomelia sequence are bilateral renal agenesis, sacral agenesis, external and internal genital defects, imperforate anus and cardiac defects.<sup>1,4,5</sup> It is controversial that sirenomelia

sequence is a variant of caudal regression syndrome or VATER syndrome. Stevenson et al<sup>6</sup> explained pathogenic mechanism of sirenomelia sequence with vascular steal phenomena and considered that sirenomelia is a distinct malformation. Also van Zalen-Sprock et al<sup>7</sup> suggested that maternal diabetes is associated with sirenomelia sequence.

In this report, we describe a case of sirenomelia sequence with a single lower limb, renal agenesis and atelencephaly.

### CASE REPORT

In Erzurum Nenehatun obstetrics and gynecology hospital, a 34-year-old gravida 2, para 0 gave birth via spontaneous vaginal delivery at 34 gestational weeks. There was no consanguinity between parents. Mother's first pregnancy resulted with spontaneous abortions due to unknown causes. Infant was alive, weighed 1640g, length 35cm, head circumference was 28cm (above the 10p). In physical examination, infant had poor general condition, prematured appearance, and central cyanosis. Dysmorphic facial features included depressed nasal bridge, and retrognathia. Patient's breathing was shallow and heart rate was bradycardic. On auscultation, diffuse crepitant rales were heard.

1. Mevlit Ikbali,
2. Hasan Kahveci,
3. Başak Adakli Aksoy,
4. Fuat Laloglu,
5. Ebru Kacmaz,
6. Muhammed Yunus Alp,

1, 6: Department of Medical Genetics,  
Karadeniz Technical University, Medical Faculty,  
Trabzon, Turkey.

2-5: Neonatal Intensive Care Unit,  
Nenehatun Obstetrics Hospital, Erzurum, Turkey.

Correspondence:

Muhammed Yunus Alp, MD,  
Department of Medical Genetics,  
Karadeniz Technical University, Medical Faculty,  
61080 - Trabzon / Turkey.  
E-mail: dryunusalp@yahoo.com

\* Received for Publication: December 22, 2011

\* Corrected and Edited: September 3, 2012

\* Accepted for Publication: September 8, 2012

Infant had a single lower limb (Fig.1), anal atresia and single umbilical artery. External genitalia was absent. At the distal end of the limb, there was a single phalanx without nail. Tracheal intubation was performed due to respiratory distress, and surfactant was administered via endotracheal way.

Prenatal fetal USG examination revealed anencephaly, renal agenesis, and single lower limb. Parents did not accept the recommendation of termination of pregnancy. On laboratory examination, routine hemogram, and biochemical tests were within normal range. USG examination revealed bilateral renal agenesis and absence of brain parenchyma. Cranial and abdominal MRI couldn't be performed due to patient's poor condition. Skeletal radiography showed sacral agenesis and hemivertebra. Fibula, bones of foot and digits were absent (Fig.2). Four hours after delivery, infant died because of the respiratory distress. Genetic analysis and autopsy couldn't be performed as the family refused for it.

## DISCUSSION

Anomalies present with sirenomelia sequence could be evaluated as related and unrelated.<sup>5</sup> Related anomalies associated with sirenomelia sequence are single lower limb, renal agenesis, genital and anorectal anomalies, single umbilical artery, low spinal column defects, and large bowel.<sup>1,5,8</sup> Unrelated anomalies have been reported with sirenomelia sequence are radial aplasia/hypoplasia, cardiac defects, central nervous system anomalies, abdominal wall defects.<sup>5</sup> Our case had characteristic features of sirenomelia sequence which are single lower limb, bilateral renal agenesis,

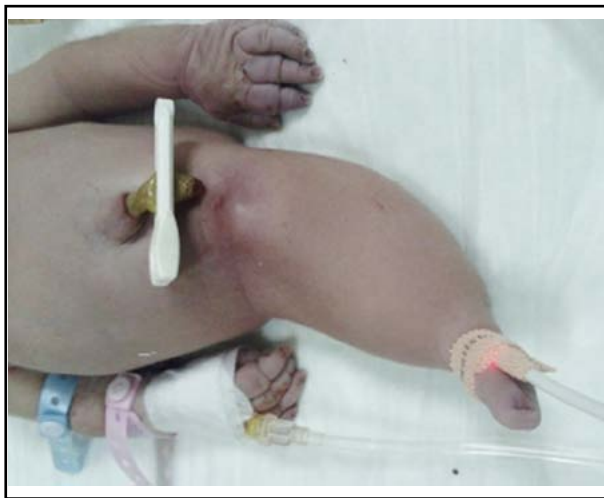

Fig.1: Infant with single lower limb and absent external genitalia.

single umbilical artery, anal atresia, absence of external genitalia, sacral agenesis and hemivertebra. As an unrelated anomaly atelencephaly was present (Fig.1).

There are two classification of sirenomelia sequence. In the first classification there are three types of sirenomelia according to the number of feet. Symelia apus presents with completely fused leg and absent feet. Symelia unipus presents one foot and symelia dipus presents two feet.<sup>9</sup> Stocker and Heifetz<sup>1</sup> classified sirenomelia in seven types according to the status of femur and fibula. In our case, there is a femur and tibia and both feet are absent (Fig.2). According to the first classification our case is symelia apus, but type 6 according to the Stocker and Heifetz.<sup>1</sup>

Etiological factors of sirenomelia sequence are still unclear. Several heterogeneous risk factors have been reported, but all of them are debatable. Chromosomal syndromes, monogenic conditions and familial recurrence were not identified in any cases. But as a part of the caudal regression syndrome familial cases were reported.<sup>5</sup> Maternal risk factors associated with sirenomelia are diabetes mellitus and younger maternal age. Maternal diabetes is reported in 2% of cases.<sup>10</sup> Orioli et al<sup>5</sup> observed that younger maternal age, less than 20, has a higher prevalence of sirenomelia. From 10 to 15 percent of sirenomelia sequence cases are in twin births, most of them monozygous, and only one fetus is affected.<sup>10</sup>

There is no clear environmental factor associated with sirenomelia sequence. Fetal exposure to cocaine and a kind of snuff have been reported

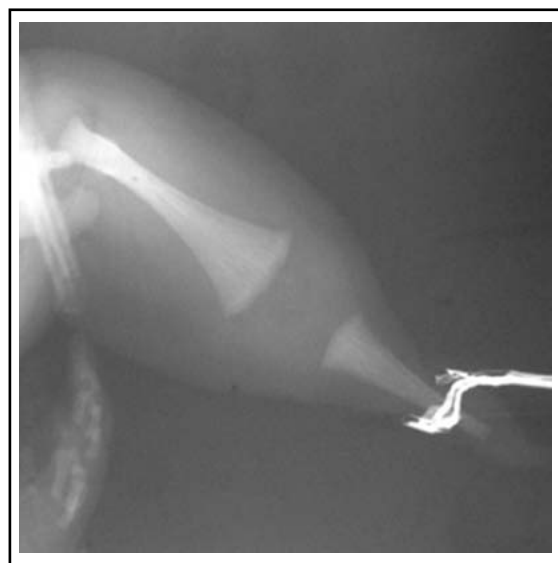


Fig.2: X-ray showing single femur and tibia.

in two sirenomelia cases.<sup>9,11</sup> Experimental animal studies showed that retinoic acid, cadmium, lead, Ochratoxin A, induced sirenomelia.<sup>12-14</sup> But Holmes<sup>15</sup> stated that there is no teratogen associated with sirenomelia. As a result of these conflicting data, more extensive epidemiologic study is needed to identify etiology of this very rare congenital malformation.

## REFERENCES

1. Stocker JT, Heifetz SA. Sirenomelia: a morphological study of 33 cases and review of the literature. *Perspect Pediatr Pathol* 1987;10:7-50.
2. Kallen B, Castilla EE, Lancaster PAL, Mutchinick O, Knudsen L, Martinez-Frias ML, et al. The cyclops and the mermaid. An epidemiological study of two types of rare malformations. *J Med Genet* 1992;29:30-35.
3. Castilla EE, Orioli IM. Eclamc: The Latin American Collaborative Study of Congenital Malformations. *Community Genet* 2004;7:76-94.
4. Stevenson RE. Limbs. In: Stevenson RE, Hall JG, editors. *Human malformations and related anomalies*, 2nd edition. New York: Oxford University Press. 2006: 866-868.
5. Orioli IM, Amar E, Arteaga-Vazquez J, Bakker MK, Bianca S, Botto LD. Sirenomelia: An epidemiologic study in a large data set from the International Clearing house of Birth Defects Surveillance and Research, and literature review. *Am J Med Genet* 2011;157:358-373.
6. Stevenson RE, Jones KL, Phelan MC, Jones MC, Barr MJR, Clericuzio C, et al. Vascular steal: the pathogenic mechanism producing sirenomelia and associated defects of viscera and soft tissues. *Pediatrics* 1986;78:451-457.
7. Van Zalen-Sprock MM, Van Vugt JMG, Van Der Harten JJ, Van Geijn HP. Early second-trimester diagnosis of sirenomelia. *Prenat Diagn* 1995;15:171-177.
8. Dicle N, Sayhan S, Ayaz D, Kececi S, Sancı M. Sirenomelia (the Mermaid Syndrome): Report of Three Cases. *Turkey Klinikleri J Med Sci* 2010;30:1392-1394.
9. Sarpong S, Headings V. Sirenomelia accompanying exposure of the embryo to cocaine. *South Med J* 1992;85:545-547.
10. Valenzano M, Paoletti R, Rossi A, Farinini D, Garlaschi G, Fulcheri E. Sirenomelia. Pathological features, antenatal ultrasonographic clues and a review of current embryogenic theories. *Hum Reprod Update* 1999;5:82-86.
11. Taghavi MM, Jafari Naveh HR, Shariati M, Morteza Zade F. Sirenomelia (mermaid syndrome): An infant from parents who used a special form of snuff. *Pak J Biol Sci* 2009;12:722-725.
12. Padmanabhan R. Retinoic acid-induced caudal regression syndrome in the Mouse fetus. *Reprod Toxicol* 1998;12:139-151.
13. Hilbelink DR, Kaplan S. Sirenomelia: Analysis in the cadmium- and lead-treated golden hamster. *Teratog Carcinog Mutagen* 1986;6:431-440.
14. Wei X, Sulik KK. Pathogenesis of caudal dysgenesis/sirenomelia induced by ochratoxin A in chick embryos. *Teratology* 1996;53:378-391.
15. Holmes LB. Teratogen-induced limb defects. *Am J Med Genet* 2002;112:297-303.