

Irreversible Horner's syndrome diagnosed by aproclonidine test due to benign thyroid nodule

Coskun M¹, Aydogan A², Gokce C³, Ilhan O⁴,
Ozkan OV⁵, Gokce H⁶, Oksuz H⁷

ABSTRACT

We are reporting an irreversible Horner Syndrome (HS) in a patient with benign thyroid gland nodule in which thyroidectomy was performed for treatment. A 37-year-old female was admitted to our clinic with a swelling in the left lobe of the thyroid gland and ptosis at the left eyelid. The clinical diagnosis of HS was confirmed pharmacologically by aproclonidine. Histopathologic examination of thyroidectomy specimen was reported as benign nodule. To the best of our knowledge, this is a very rare report in terms of thyroid benign nodule associated with irreversible HS due to cervical sympathetic chain compression.

KEY WORDS: Horner's syndrome, Thyroid nodule, Aproclonidine.

doi: <http://dx.doi.org/10.12669/pjms.291.2732>

How to cite this:

Coskun M, Aydogan A, Gokce C, Ilhan O, Ozkan OV, Gokce H, Oksuz H. Irreversible Horner's syndrome diagnosed by aproclonidine test due to benign thyroid nodule. *Pak J Med Sci* 2013;29(1):224-226. doi: <http://dx.doi.org/10.12669/pjms.291.2732>

This is an Open Access article distributed under the terms of the Creative Commons Attribution License (<http://creativecommons.org/licenses/by/3.0>), which permits unrestricted use, distribution, and reproduction in any medium, provided the original work is properly cited.

INTRODUCTION

Horner's syndrome (HS) is a triad of pupillary miosis, eyelid ptosis and anhidrosis. It is due to the disruption of the sympathetic pathways between the eye and the brain.¹

Thyroid nodules generally present as an asymptomatic mass at the gland. The differential diagnosis of a thyroid nodule consists of colloid

nodule, adenoma, lymphocytic thyroiditis, thyroglossal duct cyst, and malignancies.²⁻⁶ Compression of the cervical sympathetic chain by large benign or malignant thyroid nodule rarely may result in HS.^{7,8}

Here, we present a case diagnosed as irreversible HS due to a benign thyroid nodule. To the best of our knowledge, this is a very rare report regarding thyroid benign nodule associated with irreversible HS due to cervical sympathetic chain compression in the literature. In this report, also, the nodular goiter associated with HS is investigated and the clinical diagnosis of the disease is confirmed via pharmacological testing by aproclonidine.

CASE REPORT

A 37 years old woman was admitted to the outpatient clinic due to a swelling on her neck, left upper eyelid ptosis and miosis for two years (Fig.1 a, b). There was no palpitation, sweating and nervousness. On physical examination, there was a mass with a diameter of approximately 5 x 5 cm located at the left thyroid lobe and ptosis of the left eyelid. The thyroid functions tests in terms of free T3, free T4, TSH were normal.

1. Coskun M,
2. Aydogan A,
3. Gokce C,
Department of Endocrinology,
4. Ilhan O,
5. Ozkan OV,
6. Gokce H,
Department of Pathology,
Oksuz H,
- 1,4,7: Department of Ophthalmology,
- 2, 5: Department of General Surgery,
- 1-7: Mustafa Kemal University, Medical Faculty,
Hatay, Turkey.

Correspondence:

Mesut Coskun, MD,
Assistant Professor, Department of Ophthalmology,
Mustafa Kemal University, Medical Faculty,
31100 Hatay, Turkey.
E-mail: drmesutcoskun@hotmail.com

* Received for Publication: July 24, 2012

* Accepted for Publication: October 12, 2012

Thyroid ultrasonography displayed that there was a solitary heterogeneous nodule which is 55 x 51 mm in size located at the left upper posterior of the gland. In addition, there were two nodules at the left thyroid lobe. The larger one is hypoechogenic and has a dimension of 15 x 8 mm. The other nodule has a dimension of 7 x 5 mm, located at the posterior section of the right lobe (Fig.2a). Similar images were also observed in a computerized tomography (Fig.2b). Fine needle aspiration cytology of thyroid nodule was benign in terms of the cytological investigation.

The patient had consultation the ophthalmology department in aspect of ptosis and miosis. On the ophthalmologic examination (MC), there was left upper eyelid ptosis and miosis. Under the bright conditions, the pupil sizes were measured as 4 mm in the right eye and 2 mm in the left eye. Under the dim light, they were measured as 6 mm in the right eye and 3 mm in the left eye, and there was left pupillary dilatation lag. The pupils were equally responsive to both the light and near stimuli.

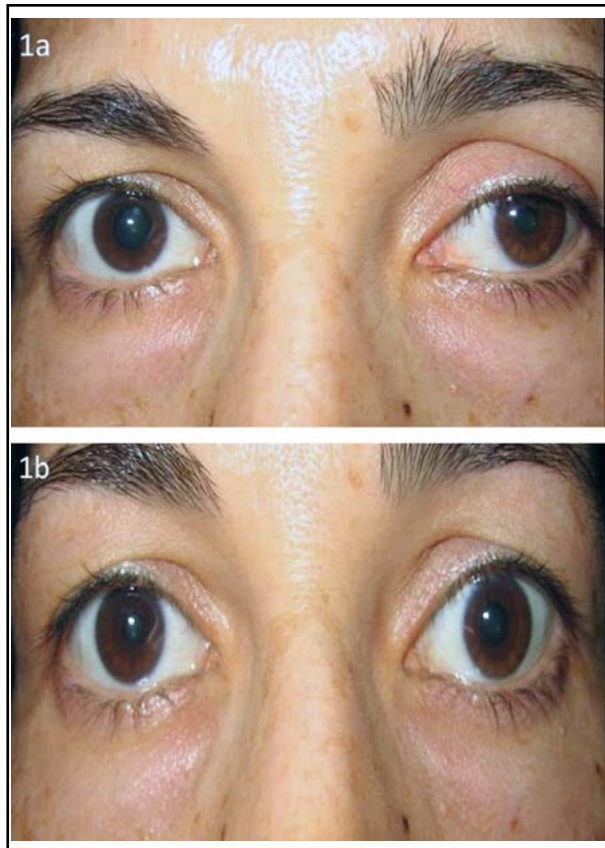


Fig.1a: 37-year-old female patient with left Horner syndrome. Fig.1b: The resolution of the anisocoria and the left upper lid ptosis after instillation of apraclonidine.

Extraocular motility was normal in the eyes. No relative afferent pupillary defect was detected. Bilaterally, intraocular pressure was normal. There was no abnormal finding by slit-lamp and at the fundus examinations of both eyes. Best corrected visual acuities were 20/20 in both of the eyes. After instillation of topical apraclonidine (0.5%), (Iopidine, Alcon Laboratories Inc, Fort Worth, Texas) the right pupil was measured as 2 mm, while the left one was measured as 4 mm, the anisocoria reversed and the ptosis was entirely resolved (Fig.1b).

The patient had thyroidectomy after giving the informed consent. Postoperative surgical specimen was consistent with a benign nodular goiter. There was no improvement in terms of HS during the last 8 months follow-up.

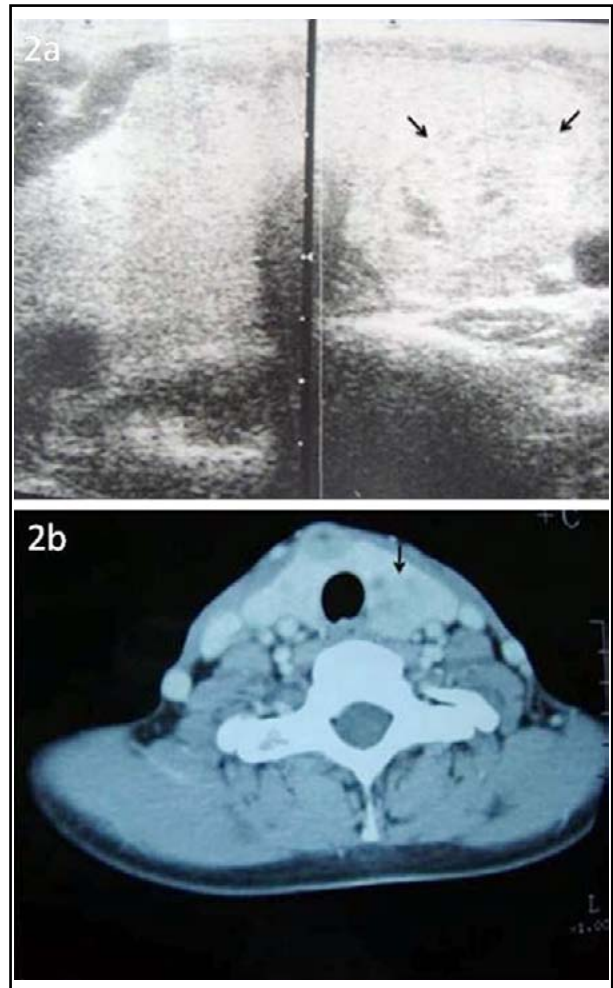


Fig.2a: Thyroid ultrasound displaying a solitary heterogeneous nodule which is 55 X 51 mm in size.

Fig.2b: Computerize tomography imaging of the neck demonstrating the same thyroid nodule.

DISCUSSION

Horner's syndrome as a result of thyroid diseases is an uncommon complication. It may be due to benign and malignant thyroid nodules.^{7,8} It is expected that the syndrome is more likely to develop in patients with malignant thyroid nodules. In the present case, HS had developed even though the thyroidal nodule was benign. In a study, a case with HS due to a benign multinodular goiter was operated and the patient's symptoms were resolved after the surgery.^{7,9} In the current report, the case had surgical treatment due to both the large thyroidal nodule and its compression on the sympathetic chains causing HS. However, no improvement in HS was observed in this patient after the surgery, and it is probably related to irreversible changes of the ocular sympathetic nerve. Therefore, it is suggested that the large nodule had been present for a long time, and resulted in irreversible HS for two years due to the nerve compression.

In previous reports, HS due to thyroidal disorders are not evaluated in detail in case of ophthalmologic investigation such as pharmacological eye tests.^{7,9} It is necessary to support the diagnosis of HS by pharmacological testing.¹⁰ If the result of the pharmacological testing is negative, then the diagnosis could be considered as pseudo-HS. Actually, in patients with pseudo-HS, the etiology of symptoms such as ptosis and anisocoria may be due to other diseases rather than HS.⁹ In the current study, the clinical diagnosis was confirmed by pharmacological testing using topical apraclonidine. Topical cocaine and hydroxyamphetamine were also previously used in the diagnosis of HS as pharmacological testing.^{10,11} Recently, aproclonidine is another drug commonly used to diagnose the HS due to its cost and ease availability.^{11,12}

Here, we present a case diagnosed as irreversible HS due to a large benign thyroid nodule confirmed by aproclonidine test. To the best of our knowledge, this is a very rare report in aspect of large thyroid benign nodule associated with irreversible HS due

to cervical sympathetic chain compression in the literature. Also, after the thyroid surgery, HS was not resolved in comparison to the some previous reports.^{7,8} In addition, pharmacological testing such as aproclonidine was used for the confirmation of the diagnosis in the current case.

In conclusion, nodular goiter associated with HS should be investigated and clinical diagnosis should be confirmed via pharmacological testing such as aproclonidine.

REFERENCES

- Walton KA, Buono LM. Horner's syndrome. *Curr Opin Ophthalmol.* 2003;14(6):357-363.
- Niedziela M. Pathogenesis, diagnosis and management of thyroid nodules in children. *Endocr Relat Cancer.* 2006;13(2):427-453.
- Altincik A, Demir K, Abaci A, Bober E, Buyukgebiz A. Fine-needle aspiration biopsy in the diagnosis and follow-up of thyroid nodules in childhood. *J Clin Res Pediatr Endocrinol.* 2010;2(2):78-80.
- Bayram F, Kulahli I, Yuce I, Gokce C, Cagli S, Deniz K. Functional lingual thyroid as unusual cause of progressive Dysphagia. *Thyroid.* 2004;14(4):321-324.
- Gokce C, Patiroglu T, Aksehirli S, Durak AC, Kelestimur F. Hydatid cyst in the thyroid gland diagnosed by fine-needle aspiration biopsy. *Thyroid.* 2003;13(10):987-989.
- Bayram F, Soyler I, Atmaca H, Demirci D, Gokce C, Canoz O, et al. Prostatic adenocarcinoma metastasis in the thyroid gland. *Endocrine J.* 2004;51(4):445-448.
- Leuchter I, Becker M, Mickel R, Dulguerov P. Horner's syndrome and thyroid neoplasms. *Orl J Otorhinolaryngol Relat Spec.* 2002;64:49-52.
- Levin R, Newman SA, Login IS. Bilateral Horner's syndrome secondary to multinodular goiter. *Ann Intern Med.* 1986;105(4):550-551.
- Martin TJ. Horner's syndrome, Pseudo-Horner's syndrome and simple anisocoria. *Curr Neurol Neurosci Rep.* 2007;7(5):397-406.
- Oksuz H, Tamer C, Melek IM. Latanaprost treatment of the heterochromia in a patient with acquired horner syndrome. *Neuro-Ophthalmology.* 2006;30(5):129-131.
- Freedman KA, Brown SM. Topical apraclonidine in the diagnosis of suspected Horner syndrome. *J Neuroophthalmol.* 2005(2);25:69-70.
- Johnson TV, Toris CB, Fan S, Camras CB. Effects of central corneal thickness on the efficacy of topical ocular hypotensive medications. *J Glaucoma.* 2008;17(2):89-99.