

## Isolated labial fusion as a cause of acute urinary retention in early adolescent period

Dilek Benk Silfeler<sup>1</sup>, Burcu Artunc<sup>2</sup>, Osman Zeki Pektas<sup>3</sup>,  
Ilhan Sanverdi<sup>4</sup>, Sadiye Eren<sup>5</sup>

### ABSTRACT

Fusion of the labia majora is generally an acquired defect because of local inflammation, trauma and vaginal lacerations. In postmenopausal period, it is associated with lichen sclerosis. It is typically found in young neonates or prepubertal girls when the labia and vagina are not adequately estrogenized. In this study, a 14-year adolescent with labial fusion as a cause of acute urinary retention is presented.

**KEY WORDS:** Labial fusion, Urinary retention, Adolescent.

Pak J Med Sci April - June 2011 (Part-II) Vol. 27 No. 3 708-710

### How to cite this article:

Silfeler DB, Artunc B, Pektas OZ, Sanverdi I, Eren S. Isolated labial fusion as a cause of acute urinary retention in early adolescent period. Pak J Med Sci 2011;27(3):708-710

### INTRODUCTION

Labial fusion is partial or complete adhesion of the labia majora and/or labia minora. In the etiology, inadequate estrogen levels and erosion of the vulvar epithelium because of the recurrent irritation are the typical predisposing factors.<sup>1,2</sup> Fusion of the labia minora is mostly a pediatric condition seen from three months to three years of age.<sup>3</sup> In adults, labial fusion is associated with local inflammation, vaginitis, hypoestrogenism, local vulvar trauma, vaginal laceration or untreated urinary system infections.<sup>4,5</sup>

Prepubertal girls with labial fusion may not have any symptoms. When symptomatic, main complaints are urinary retention and difficulty in voiding. In this study, a 14-year adolescent with adequate estrogen levels is presented with acute urinary retention because of labial fusion.

### CASE REPORT

A 14-year-old sexually inactive adolescent was admitted to our clinic with severe abdominal pain and difficulty in voiding. Her menarche was 1.5 years ago, her period was regular with three pads a day. She had never been sexually active. She only had spotting for the last three months and she could void only with effort for one year. On physical examination, she had general abdominal sensitivity. There was complete adhesion of labia majora (Fig-1). The uterus and bilateral ovaries were normal on abdominopelvic ultrasonographic examination (Fig-2). The bladder was full and there was a huge hypocoecogenic image in the vagina. On the gynecological examination table, a cleavage was found and opened via a clamp through labia majora (Fig-3).

Great amount of urine was discharged from the opened channel. On abdominopelvic ultrasonographic examination, the image in the vagina was lost. The patient voided again with effort to discharge the rest of urine in the bladder. This first stage procedure is

1. Dilek Benk Silfeler,  
Department of Gynecology, Faculty of Medicine,  
Mustafa Kemal University, Hatay, Turkey
2. Burcu Artunc,
3. Osman Zeki Pektas,
4. Ilhan Sanverdi,
5. Sadiye Eren,
- 2-5: Zeynep Kamil Hospital,  
Istanbul, Turkey.

Correspondence:

Dilek Benk Silfeler,  
Alaattin koyu, Gungor uydukent 30 parsel,  
D11/3 Antakya,  
Hatay, Turkey.  
E-mail: drsilfeler@gmail.com

- \* Received for Publication: August 17, 2010
- \* Revision Received: March 22, 2011
- \* Revision Accepted: March 25, 2011

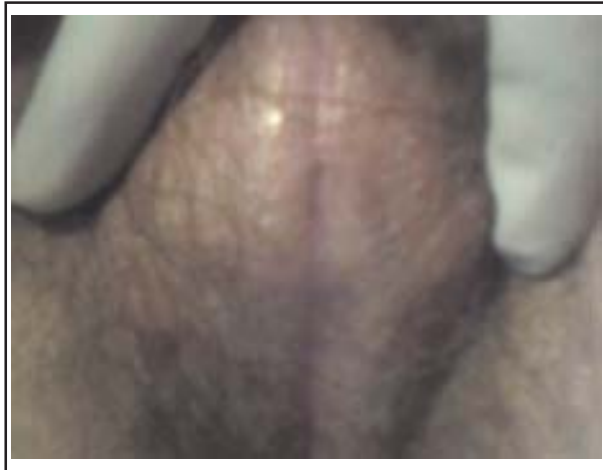

Fig-1: Complete adhesion of labia majora.

used for threatening the pain of acute urine retention in the patient. During acute period, the separation surgery was guided after providing mixture. She was prepared for the operation after her general condition was better. There was no sign of any urinary system infection. Her estrogen levels were normal. She had regular periods. She had normal secondary sexual characteristic development. There were no symptoms on her skin, so an excisional skin biopsy was not considered. Under general anesthesia, the adhesions of labia majora were separated with blunt dissection.

Thereafter with sharp dissection, labia minora were separated from each other and also vertically from the labia majora. The labia majora, labia minora, the orifice of urethra and clitoris now could be clearly distinguished (Fig-4). Each of the three sulci were

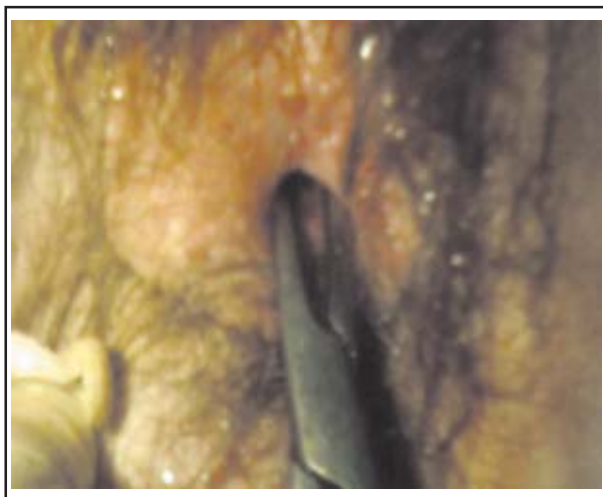

Fig-3: A cleavage was found and opened via a clamp through labia majora. Great amount of urine was discharged from the opened channel.

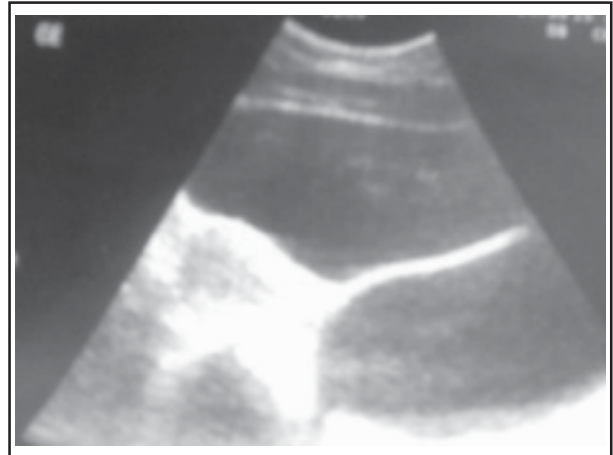


Fig-2: The huge hypoecogenic image filling the vagina.

dressed separately, because we observed that labium minus was also cohesive after labium majus was separated. She was advised to use antibiotics and estrogen creams, and have sitting baths with disinfectant solution three times a day. She was discharged from the hospital on postoperative 2<sup>nd</sup> day. On postoperative 10<sup>th</sup> day, there was a small amount of hyperemia. Six weeks later, the gynecological examination revealed that the vulvar anatomic construction worked well.

## DISCUSSION

Fusion of the labia minora is mostly a pediatric condition seen from three months to three years of age. In newborn period, it is not evident. During childhood, the incidence of labial fusion is 1.8%.

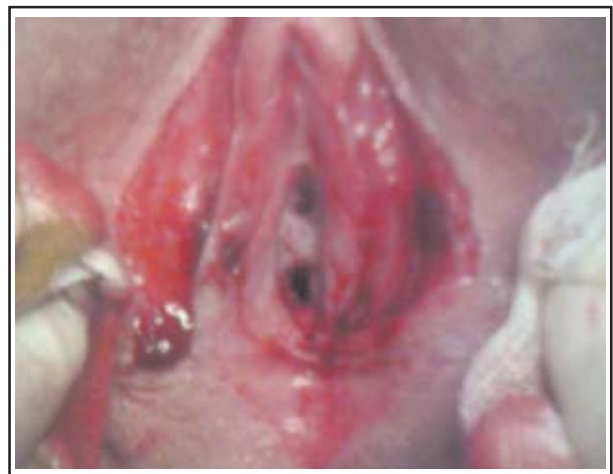

Fig-4: With sharp dissection, labia minora were separated from each other and also vertically from the labia majora. Examination of the vulva after the separation revealed a normal vagina & urethral opening.

Moreover, between 13-23 months of life, the incidence is up to 3.8%.<sup>1,7</sup> It may play a role in the etiology of labial fusion because of low estrogen levels in prepubertal or postmenopausal period. Labial fusion is generally encountered due to hypoestrogenism or chronic skin condition in the reproductive age group.<sup>1,7,8</sup> In postpartum period, labial fusion can occur as a result of lacerations after normal vaginal delivery.<sup>1,8,9</sup> Our case was in an early adolescent period and moreover she had normal estrogen levels. She was admitted to the clinic with acute abdomen. She did not have any predisposing factors but only she was sexually inactive. She had no chronic medical illness. Her gynecological hygiene was good.

In such cases it is extremely important to perform a detailed physical examination. With a proper sexual education during early adolescent period, the case could be diagnosed earlier and the treatment with topical estrogen creams could succeed without any need for a surgery.

It is not usual for labial fusion coexisting with any urinary system abnormality. Some studies mentioned that early grade lichen sclerosis can coexist with urinary morbidities.<sup>7</sup> Most of these patients are in their postmenopausal period. They have pruritus on the vulva. Topical steroid creams are used for treatment instead of estrogen creams.<sup>4,6</sup>

In the case, both vesical and vaginal urine retention occurred, although lichen sclerosis or chronic trauma weren't seen in the etiology due to fusion. The patient needed an emergency approach because of

acute retention. Therefore, we considered the patient as worthy for presentation. Labial fusion is generally a pediatric condition, however it can be evident at any age of life. It can be a rare cause of obstructive uropathy. The clinician should keep in mind that this problem can also cause voiding difficulties.

## REFERENCES

1. Soylu A, Sarier M, Davarci M, Baydinc YC. Labial fusion causing micturitional disturbance. *Turkish Urology J* 2004;30(1):117-119.
2. Papagianni M, Stanhope R. Labial adhesions in a girl with isolated premature the larche: The importance of estrogenization. *J Pediatr Adolesc Gynecol* 2003;16:31-32.
3. Topcuoglu MA, Koc O, Duran B, Donmez. Labial fusion causing acute urinary retention in a young adult: A case report. *Australian New Zealand J Obstet Gynaecol* 2009;49:115-117.
4. Acharya N, Mandal AK, Ranjan P, Kamat R, Kumar S, Singh SK. Labial fusion causing pseudo incontinence in an elderly woman. *Int J Gynaecol Obstet* 2007;99(3):246-247.
5. Nour NM. Urinary calculus associated with female genital cutting. *Obstet Gynecol* 2006;107:521-523.
6. Erkanli S, Simsek E, Haydardedeoglu B, Parlakgumus A, Kuscu E. Labial fusion developing in a 40-year old premenopausal woman. *Turkish Gynecology Obstetrical Assoc J* 2006;3(5):359-361.
7. Velander MH, Mikkelsen DB, Bygum A. Labial agglutination in a prepubertal girl: Effect of topical oestrogen. *Acta Derm Venereol* 2009;89(2):198-199.
8. Putran J, Khaled MA, Almusawa S. Labial fusion in the reproductive age group: A rare presentation. *Gynecol Surg* 2008;5:313-314.
9. Seehusen DA, Earwood JS. Postpartum labial adhesions. *J Am Board Fam Med* 2007;20(4):408-410.