

## Kaposi's varicelliform eruption complicating irritant contact dermatitis

Serpil Sener<sup>1</sup>, Hatice Gamze Bayram<sup>2</sup>,  
Yelda Karıncaoglu<sup>3</sup>, Mustafa Senol<sup>4</sup>

### ABSTRACT

Kaposi's varicelliform eruption (KVE) or eczema herpeticum is a disseminated viral infection superimposed on pre-existing dermatosis. It is frequently caused by Herpes simplex and certain other viruses. It may result on life-threatening viraemia with multiorgan involvement and secondary infections. We report a 34-year old female patient with KVE which is caused by herpes virus developed on irritant contact dermatitis because of its rare occurrence.

**KEY WORDS:** Kaposi's varicelliform eruption, Irritant contact dermatitis.

Pak J Med Sci January - March 2012 Vol. 28 No. 1 225-227

### How to cite this article:

Sener S, Bayram HG, Karıncaoglu Y, Senol M. Kaposi's varicelliform eruption complicating irritant contact dermatitis. Pak J Med Sci 2012;28(1):225-227

### INTRODUCTION

Kaposi's varicelliform eruption (KVE) or eczema herpeticum describes acute, disseminated cutaneous eruption caused by herpes simplex virus type 1 and 2, and rarely vaccinia virus or Coxsackie A16 virus that infect persons with preexisting dermatosis.<sup>1</sup> Most commonly it is associated with atopic dermatitis.<sup>2</sup> Multiple skin disorders have been less frequently associated with KVE. It may progress to fulminating and can have severe sequelae so antiviral treatment should be instituted without delay to avoid significant morbidity and mortality.

1. Serpil Sener, MD,
2. Hatice Gamze Bayram, MD,
3. Yelda Karıncaoglu, MD,
4. Mustafa Senol, MD,
- 1-4: Department of Dermatology,  
Inonu University School of Medicine,  
Turgut Ozal Medical Center,  
Malatya, Turkey.

#### Correspondence:

Serpil Sener, MD,  
Department of Dermatology,  
Inonu University School of Medicine,  
Turgut Ozal Medical Center, 44315,  
Malatya, Turkey.  
E-mail: senerserpil@hotmail.com

- \* Received for Publication: February 3, 2011
- \* Accepted for Publication: May 4, 2011

### CASE REPORT

A 34-year old woman presented with diffuse vesiculopustular eruption along with fever and malaise. The eruption had begun on the lower lip and gradually spread to the entire face, trunk and extremities. She had pre-existing eczematous dermatitis as irritant contact dermatitis and she was not having any treatment.

Physical examination revealed an umbilicated vesiculopustular rash on her face, trunk and extremities (Fig.1, Fig.2, Fig.3). She had erythema on both wrists (Fig.4). The ophthalmologic involvement of herpetic infection was negative. Bilateral servical lymphadenopathy was palpated. The rest of her physical examination was unremarkable.

Laboratory examination including complete metabolic panel, blood count, urinalysis and liver function studies revealed neutrophilia and high sedimentation rate (60mm/h). A Tzanck preparation from an umbilicated vesicle showed multinucleated giant cells along with the acantholytic cells. The vesicle fluid was positive for HSV-1 on direct immunofluorescence test. Her serum anti HSV-1 IgM antibody was found to be positive. Histologic examination of an umbilicated vesicle taken from the forearm showed intraepidermal vesicle and pustule formation with ballooning degeneration in the periphery.

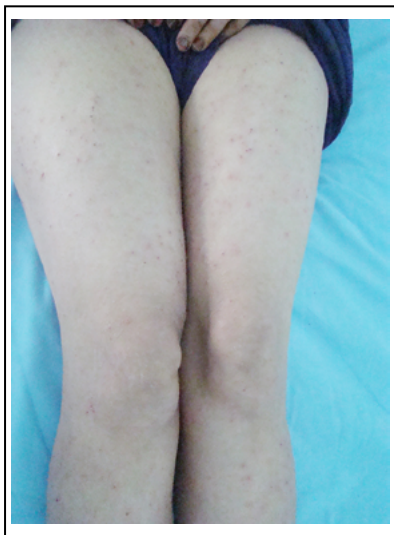


Fig-1: Diffuse vesiculopustular rash on her legs.

The diagnosis of the KVE on pre-existing irritant contact dermatitis was supported by Tzanck test in addition to histologic evaluation, and confirmed by the detection of anti HSV- 1 IgM. The patient was treated with bed rest, rehydration and acyclovir (15mg/kg) three times a day by intravenous route for 10 days. Oral ampicillin-sulbactam treatment was added to decrease the probability of secondary infection. In addition to systemic treatment, antiseptic wet dressing was applied. Lesions rapidly responded to the treatment. All crusted vesiculopustular lesions showed a complete healing within two weeks.

### DISCUSSION

KVE is a potentially life-threatening secondary viral infection that affects patients in the setting of primary skin conditions.<sup>3</sup> It occurs with various

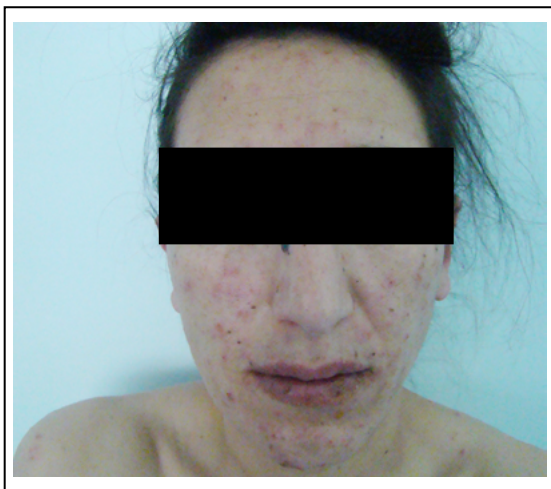

Fig-3: Umbilicated vesiculopustular eruption on her face.

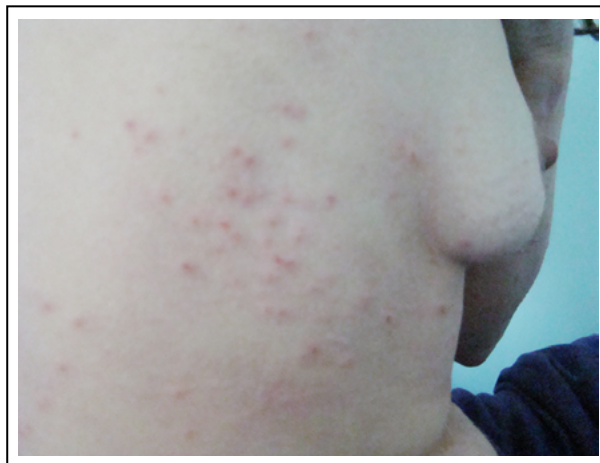

Fig-2: Diffuse vesiculopustular rash on her trunk.

skin diseases, such as atopic dermatitis, Wiskott-Aldrich syndrome, pemphigus foliaceus, ichthyosis vulgaris, bullous pemphigoid, seborrheic dermatitis, psoriasis, irritant contact dermatitis and Darier's disease.<sup>1-4</sup> Mycosis fungoides, burns, traumatic facial abrasions may very rarely be complicated by KVE.<sup>5-7</sup>

Disruption of the epidermal barrier and impairment of humoral or cellular immunity have been proposed to explain the development of Kaposi's varicelliform eruption.<sup>8</sup> Topical calcineurin inhibitors, which are commonly used to treat atopic dermatitis, have been associated with development of KVE.<sup>9</sup> Our patient did not have a story of topical or systemic drug use.

KVE usually begins as vesiculopustules which are umbilicated on skin affected by a pre-existing dermatitis and may be accompanied by fever, chills and malaise. The vesiculopustules rapidly

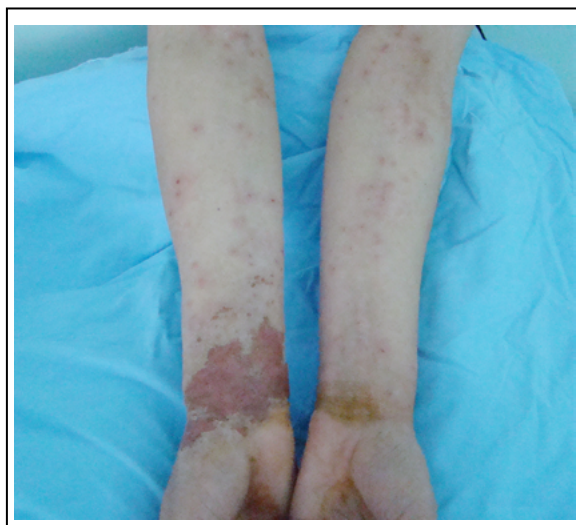


Fig-4: Irritant contact dermatitis on her both wrists.

become painful hemorrhagic, crusted, punched-out erosions.<sup>1</sup> It may progress to fulminating and can have severe complications, including superimposed bacterial infections, permanent visual impairment due to herpes keratitis, and disseminated infection with visceral involvement and death.<sup>3</sup>

Irritant contact dermatitis is a non-specific inflammatory dermatosis, mainly due to the toxicity of chemicals on the skin cells. Chapped skin from handwashing due to frequent exposure to water and detergent is a typical example.<sup>10</sup>

In our case, KVE was associated with irritant contact dermatitis which occurred after detergent contact. The herpes simplex virus infection appeared first on the lower lip and then spread simultaneously through healthy skin. Our diagnosis was made based on clinical features, Tzanck smear, serology and histological examination. The patient responded adequately to antiviral and antibacterial therapy. In conclusion, early recognition of Kaposi's varicelliform eruption and appropriate treatment with antiviral drugs and antibiotics are paramount for preventing complications.

## REFERENCES

1. Wollenberg A, Zoch C, Wetzel S. Predisposing factors and clinical features of eczema herpeticum: A retrospective analysis of 100 cases. *J Am Acad Dermatol* 2003;49:198-205.
2. Leyden JJ, Baker DA. Localized herpes simplex infections atopical dermatitis. *Arch Dermatol* 1979;115:311-312.
3. Fitzpatrick JE, Aeling JL. *Dermatology Secrets in Color*. 2nd Ed; Philadelphia; Hanley & Belfus, 2001:175-176.
4. Mackley CL, Adams DR, Anderson B, Miller JJ. Eczema herpeticum: A dermatologic emergency. *Dermatol Nurs* 2002;14:307-10, 323; quiz 313
5. Hayashi S, Yamada Y, Dekio S, Jidoi J. Kaposi's varicelliform eruption in a patient with mycosis fungoides. *Clin Exp Dermatol* 1997;22:41-43.
6. Bartralot R, Garcia-Patos V, Rodriguez-Cano L, Castells A. Kaposi's varicelliform eruption in a patient with healing second degree burns. *Clin Exp Dermatol* 1996;21:127-130.
7. Bestue M, Cordero A. Kaposi's varicelliform eruption in a patient with healing peribuccal dermabrasion. *Dermatol Surg* 2000;26:939-940.
8. Segura S, Romero D, Carrera C. Eczema herpeticum during treatment of atopical dermatitis with 1% pimecrolimus cream. *Acta Derm Venereol* 2005;85:524-525.
9. Lubbe J, Pournaras CC, Saurat JH. Eczema herpeticum during treatment of atopical dermatitis with 0.1% tacrolimus ointment. *Dermatology* 2000;201:249-251.
10. Slodownik D, Lee A, Nixon R. Irritant contact dermatitis: A review. *Australas J Dermatol* 2008;49:1-9.