

Association of steatosis with histopathological grading and staging of liver biopsies in hepatitis C patients

Shuja Izhar Syed¹, Saleem Sadiq²

ABSTRACT

Objective: To find out the association of steatosis with histopathological grading and staging of liver biopsies in hepatitis C patients.

Methodology: This was a prospective study based on liver biopsies of hepatitis C patients. H and E stained slides were examined to determine the histological activity, fibrosis score and steatosis.

Results: Out of 50 patients, 28 cases had some degree of steatosis. Out of the total 22 cases with grade one activity maximum number of 14 cases had revealed no steatosis. Majority of the patients with higher grades of steatosis (12 out of 13 patients) had demonstrated severe necroinflammatory score. A significant correlation of steatosis with fibrosis ($p < 0.005$) was also evident from this study.

Conclusion: Steatosis is an important cofactor in increasing liver necroinflammatory activity and fibrosis in chronic hepatitis C. Steatosis could therefore be a marker of necroinflammation and a marker of fibrosis progression.

KEY WORDS: Liver Biopsy, Hepatitis C, Necroinflammatory activity, Grade, Stage, Steatosis.

Pak J Med Sci April - June 2011 (Part-II) Vol. 27 No. 3 638-640

How to cite this article:

Syed SI, Sadiq S. Association of steatosis with histopathological grading and staging of liver biopsies in hepatitis C patients. Pak J Med Sci 2011;27(3):638-640

INTRODUCTION

Hepatic steatosis is defined as excessive lipid accumulation within the hepatocyte cytoplasm and has been more recently recognized as a significant cause for cirrhosis. There are two forms of steatosis present in patients with hepatitis C, specifically metabolic steatosis and HCV-induced steatosis. Metabolic steatosis is not triggered in any way by the hepatitis C virus, however the combination of this form of steatosis and the presence of HCV has been associated with a more rapid progression of fibrosis.

Though the precise mechanism is not well known, HCV-induced steatosis is recognized as the sole route for a direct cytopathic effect by the hepatitis C virus.¹ There are several mechanisms which may account for the relationship between steatosis and necroinflammation. In vitro studies have shown that the HCV core protein could lead to oxidative stress. Moreover, HCV is associated with increased production of cytokines that enhance inflammation and lead to increased lipid peroxidation.² The presence of steatosis on liver biopsy in patients with hepatitis C is more frequent when compared to other chronic liver disease such as chronic hepatitis B and autoimmune hepatitis. Steatosis present in patients with HCV is also distributed in the periportal areas rather than the centrilobular region which is more commonly seen in known alcoholic fatty liver disease. This all infers that the hepatitis C virus may be directly inducing steatosis in these patients rather than simply being an unrelated finding.¹ Khokhar et al 2004 in Rawalpindi have found that over 60% of patients with hepatitis C had varying degrees of steatosis and found it to be associated with more rapid progression of fibrosis.³

1. Dr. Shuja Izhar Syed, MBBS, M.Phil
Assistant Professor, Department of Pathology
Baqai Medical University, Karachi, Pakistan.
2. Dr. Saleem Sadiq, MBBS, M.Phil
Professor, Department of Pathology,
Basic Medical Sciences Institute,
Jinnah Postgraduate Medical Center, Karachi, Pakistan.

Correspondence:

Dr. Shuja Izhar Syed, MBBS, M.Phil,
E-mail: shujaizhar@yahoo.com

- * Received for Publication: January 27, 2011
- * Revision Received: May 5, 2011
- * Revision Accepted: May 15, 2011

Not many studies regarding steatosis and its relation with histopathological grading and staging of hepatitis C are available. It was therefore decided to carry out this study on association of steatosis with histopathological grading and staging of liver biopsies in hepatitis C patients.

METHODOLOGY

This was a prospective study based on liver biopsies of hepatitis C patients received at the Department of Pathology at Basic Medical Sciences Institute (BMSI), Jinnah Postgraduate Medical Center, Karachi during the period from 01-09-2007 to 31-07-2008 and was carried out in collaboration with the Department of Radiology, Jinnah Postgraduate Medical Center, Karachi.

Fifty patients who were serologically positive for hepatitis C were included in the study. These patients after consent underwent ultrasound guided liver biopsies at the department of Radiology. These biopsies were received at the Department of Pathology, BMSI for histopathological evaluation. The formalin fixed specimens were embedded in the paraffin after tissue processing. Sections were taken and stained with H&E, PAS, Trichrome and Perl's stain.

The stained slides were examined under the microscope. METAVIRS' system was followed for histological grading and staging.⁴ Steatosis was graded as 1+, involving up to 25% of hepatocytes; 2+, 25% to 50% of hepatocytes; 3+, 50% to 75% of hepatocytes, and 4+, greater than 75% of hepatocytes.⁵ The following parameters were recorded in the proformas:

- 1- Histological grading and staging corresponding to the necroinflammatory score and fibrosis score respectively.
- 2- Grading of steatosis.

Statistical analysis: Chi-square test was applied to the distribution of histological features according to steatosis and their association with each other. 'P' values of < 0.005 were considered significant.

RESULTS

Out of total 50 patients 28 (56%) cases had some degree of steatosis. Out of the total 22 (44%) cases

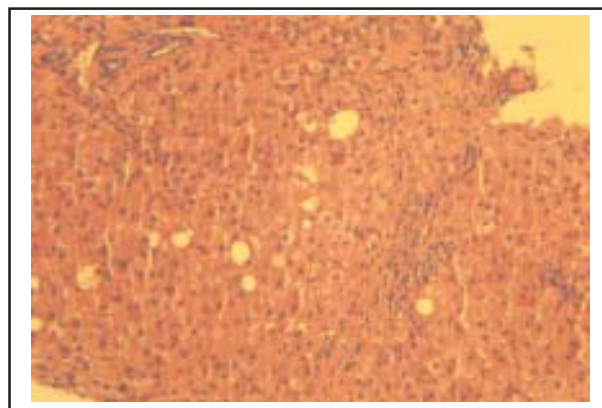


Fig-1: Steatosis grade 1, H&E, x100.

with grade one activity maximum number of 14 cases had revealed no steatosis. On the other hand out of 21 (42%) cases with grade 3 activity, 5 cases had grade 3 steatosis and 7 cases had grade 4 steatosis. (Table-I) Majority of cases with minimal or no fibrosis i.e. 18 (36%) cases and 15 (30%) cases respectively had no steatosis in 10 cases and 11 cases respectively, whereas out of 9 (18%) cases of cirrhosis, 4 cases had maximum grade of steatosis and 3 cases had grade 3 steatosis. (Table-II) None of the patients with minimal or no fibrosis had grade 3 or 4 steatosis. Similarly none of the patients with severe fibrosis and cirrhosis were found to be having absent steatosis.

DISCUSSION

In our study of 50 patients, more than half i.e. 28 (56%) cases had some degree of steatosis. (Table-I). It is somewhat comparable to Khokhar et al³ who had reported steatosis in 61.5% of patients. Adinolfi et al had found 48% of patients showing steatosis.⁶

It is evident from our study that out of 22 patients having no steatosis, the maximum number of patients i.e. 14 had shown mild necroinflammatory score. Majority of the patients with higher grades of steatosis (12 out of 13 patients) had demonstrated severe necroinflammatory score. (Table-I). This is in accordance with Adinolfi et al⁶ who had found patients with higher grade steatosis revealing a higher necroinflammatory score than those patients without steatosis ($p < 0.005$). Our data indicates that

Table-I: Comparison of necroinflammatory score (grade) with degree of steatosis.

Grade	Steatosis (grade)					Total
	0	+	++	+++	++++	
1 (mild)	14(28%)	3(6%)	5(10%)	-	-	22 (44%)
2 (moderate)	5(10%)	1(2%)	-	-	1(2%)	7 (14%)
3 (severe)	3(6%)	6(12%)	-	5(10%)	7(14%)	21 (42%)
Total	22(44%)	10(20%)	5(10%)	5(10%)	8(16%)	50

Chi .sq.: 29.9 ,Chi.sq. tab: 21.95, ($p < 0.005$)

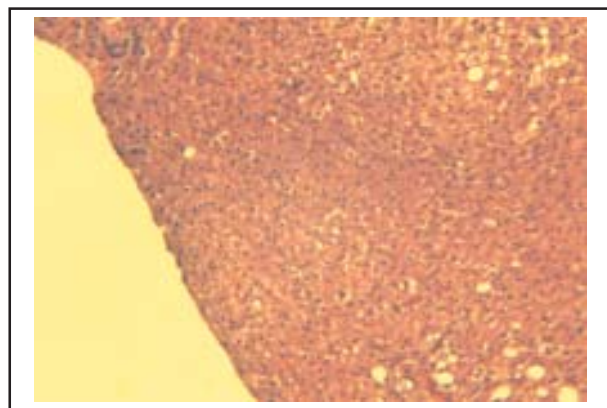


Fig-2: Steatosis grade 2, H&E, x100.

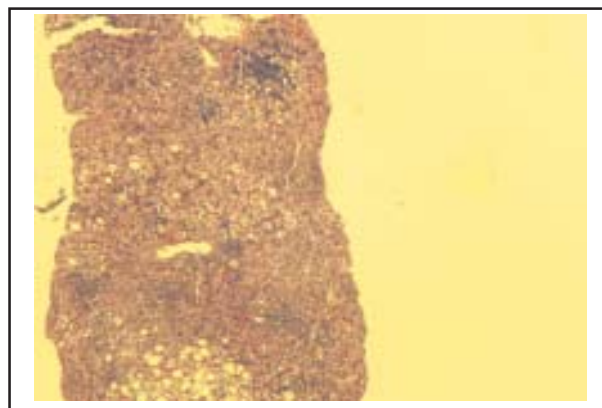


Fig-3: Steatosis grade 4, H&E, x40.

steatosis is an important cofactor in increasing liver necroinflammatory activity in chronic hepatitis C. Mihm et al⁷ and Rubbia-Brandt⁸ had also found positive association between steatosis and necroinflammatory activity.

However a recent study by Zubair A et al⁹ had not found any positive correlation of steatosis with the necroinflammatory activity, as they had used HAI scoring for the grading the activity rather than the METAVIRS' system which is utilized in our study and it stands to be the most latest and perfect system in comparison to the other systems, that might be the reason for the results.

A significant correlation of steatosis with fibrosis ($p < 0.005$) is also evident from this study. Out of 22 patients with grade 0 steatosis, 11 patients had no fibrosis whereas 10 patients had minimal fibrosis. (Table-II). It is also seen that the majority of patients i.e. 11 out of 13 patients with higher grade steatosis were found to have higher stage of fibrosis. Adinolfi et al⁶ had observed a correlation between grade of steatosis and fibrosis ($p < 0.001$), they found a mean fibrosis of 1.2 in patients with absent steatosis. They also found a mean fibrosis of 2.7 in patients with maximum steatosis. Similarly Mihm et al⁷, Rubbia-Brandt⁸ and Zubair A et al⁹ had also found significant correlation between steatosis and fibrosis. HCV genotype 3 is clearly associated with

steatosis (viral steatosis), which itself is associated with fibrosis progression. Obesity has been related to the risk of cirrhosis is an argument for a role of metabolic steatosis in the progression of fibrosis. In several studies, among alcoholics and patients with HCV infection, obesity favoured fibrosis.²

It can be concluded from this study that steatosis is an important cofactor in increasing liver necroinflammatory activity and fibrosis in chronic hepatitis C. Steatosis could therefore be a marker of necroinflammation and a marker of fibrosis progression.

REFERENCES

1. Yoon EJ, Hu KQ. Hepatitis C virus (HCV) infection and hepatic steatosis. *Int J Med Sci* 2006;3:53-56.
2. Asselah T, Rubbia-Brandt L, Marcellin P, Negro F. Steatosis in chronic Hepatitis C: Why does it really matter? *Gut* 2006;55:123-130.
3. Khokhar N, Mushtaq M, Mukhtar AS, Ilahi F. Steatosis and chronic hepatitis C virus infection. *J Pak Med Assoc* 2004;54:110-112.
4. Bedossa P, Poynard T and the French METAVIR Cooperative Study Group. An algorithm for grading activity in chronic hepatitis C. *Hepatology* 1996;24:289-293.
5. Kanel GC, Korula J. Alcoholic liver disease. In: *Atlas of liver pathology*, Saunders, 1992: 53-65.
6. Adinolfi LE, Gambardella M, Andreana A, Franc M, Tripodi O, Utili R, et al. Steatosis Accelerates the Progression of Liver Damage of Chronic Hepatitis C Patients and Correlates With Specific HCV Genotype and Visceral Obesity. *Hepatology* 2001;33:1358-1364.
7. Mihm S, Fayyazi A, Hartmann H, Ramadori G. Analysis of histopathological manifestations of chronic hepatitis C virus infection with respect to virus genotype. *Hepatology* 1997;25:735-739.
8. Rubbia-Brandt L. Hepatocyte steatosis is a cytopathic effect of hepatitis C virus genotype 3. *J Hepatol* 2000;33:106-15.
9. Zubair A, Mubarik A, Jamal S, Arif A, Khan DA. Correlation of steatosis with fibrosis & necroinflammation in chronic hepatitis C infection in the absence of confounding factors. *JCPSP* 2009;19(7):417-420.

Table-II: Correlation of fibrosis score (stage) with degree of steatosis.

Grade	Steatosis (grade)					Total
	0	+	++	+++	++++	
0	11(22%)	2(4%)	2(4%)	-	-	15 (30%)
1	10(20%)	5(10%)	3(6%)	-	-	18 (36%)
2	1(2%)	1(2%)	-	-	2(4%)	4 (8%)
3	-	-	-	2(4%)	2(4%)	4 (8%)
4	-	2(4%)	-	3(6%)	4(8%)	9 (18%)
Total	22(44%)	10(20%)	5(10%)	5(10%)	8(16%)	50

Chi. Sq.: 45.7, Chi. Sq.tab: 34.3, $p < 0.005$