

A case of wooden foreign body retained in the calcaneus

Savas Guner¹, M.Fethi Ceylan², Daghan Isik³,
S. Ilkay Guner⁴, Levent Ediz⁵

ABSTRACT

Detection of wooden foreign bodies in the extremities still remains a problem despite the developments in imaging methods. Direct X-Rays, ultrasonography, computed tomography and magnetic resonance imaging are utilized for detection of foreign bodies in the body. In this report, we have presented a case in which no findings suggestive of a foreign body were detected on ultrasonography and magnetic resonance imaging, and which underwent a surgical intervention with the prediagnosis of osteomyelitis of the calcaneus.

KEY WORDS: Foreign body, Osteomyelitis, Delayed presentation.

Pak J Med Sci July - September 2011 Vol. 27 No. 4 932-934

How to cite this article:

Guner S, Ceylan MF, Isik D, Guner SI, Ediz L. A case of wooden foreign body retained in the calcaneus. Pak J Med Sci 2011;27(4):932-934

INTRODUCTION

Foreign bodies embedded in the extremities are frequent causes for consultations in emergency rooms. Foreign bodies usually comprise metal, wooden, plastic or glass pieces. Failure to remove or to diagnose of foreign body may lead to outcomes such as allergy, inflammation or infection.¹

Most foreign bodies retained in the extremities are superficial and cause temporary discomfort.² They are most frequently seen in the hands, followed by the feet.³ Detection of foreign bodies deeply located in the extremities is not easy, despite the developments in imaging techniques. Computed tomography (CT), magnetic resonance imaging (MRI) and ultrasonography (US) are the methods utilized in the detection of wooden materials retained in the body.^{1,3}

CASE REPORT

A 16-year-old male patient presented to the orthopedics outpatient clinic with complaints of swelling, erythema and pain in his left heel. On physical examination, swelling and erythema were observed in his left heel. Palpation of this region revealed extreme tenderness. On the blood analyses, C-reactive protein was 6 mg/l, erythrocyte sedimentation rate was 20 mm/h, and white blood cell count was 12000/mm³. Radiological tests were performed. Findings suggestive of osteomyelitis were observed on direct radiography (Fig.1) and while on MRI, no foreign body was detected. On soft tissue UltraSonography edema was detected in the soft tissue.

1. Savas Guner, MD, Assistant Professor, Department of Trauma and Orthopedic Surgery, Medical School,
2. M Fethi Ceylan, MD, Assistant Professor, Department of Trauma and Orthopedic Surgery, Medical School,
3. Daghan Isik, MD, Assistant Professor, Department of Plastic Surgery,
4. S. Ilkay Guner, PhD, School of Nursing,
5. Levent Ediz, MD, Assistant Professor, Department of Physical Medicine and Rehabilitation,
- 1-5: Yuzuncu Yil University, Van, Turkey,

Correspondence:

Savas Guner, MD,
Maras cad. Yuzuncu Yil Universitesi Tip Fakultesi,
Ortopedi ve Trv. A.D,
Van, Turkey.
E-mail: gunersavas@hotmail.com

- * Received for Publication: February 1, 2011
- * Revision Received: June 7, 2011
- * Revision Accepted: June 16, 2011

In his medical history, it was learnt that he had presented to the emergency room with the complaint of a piece of wood having pricked his left heel while walking in the forest 10 months ago; the wooden piece had been removed from the heel by an emergency physician and he had been discharged on antimicrobial therapy due to absence of a foreign body on plain radiography. Six months later, the patient had presented to another orthopaedics clinic with the complaints of pain and swelling in his left heel. Oral antibiotics had been commenced with the diagnosis of soft tissue infection as a result of C-reactive protein and erythrocyte sedimentation rate, plain X-Rays and soft tissue US.

Having been diagnosed with calcaneus osteomyelitis, the patient was planned to undergo an operation. Two pieces of wood embedded in the lateral wall of the calcaneus were detected during the operation (Fig.2). The foreign bodies were removed. The samples were sent for pathological and microbiological assessment following surgical debridement of the infected and dead tissues. No growth was obtained on culture. The result of the histopathological examination was reported as osteomyelitis. The patient underwent intravenous antibiotherapy for 3 weeks and oral antibiotherapy for 3 weeks. The patient recovered without sequelae.

DISCUSSION

Although foreign body-related penetrating injuries of the extremity are common, foreign bodies in bone tissue are rarely seen.³ Making a diagnosis based on the history is quite easy in acute foreign body injuries. However, making a diagnosis becomes difficult in neglected or older cases or when it is thought that the foreign body has been completely removed.⁴ Difficulty in diagnosing wooden foreign bodies is a

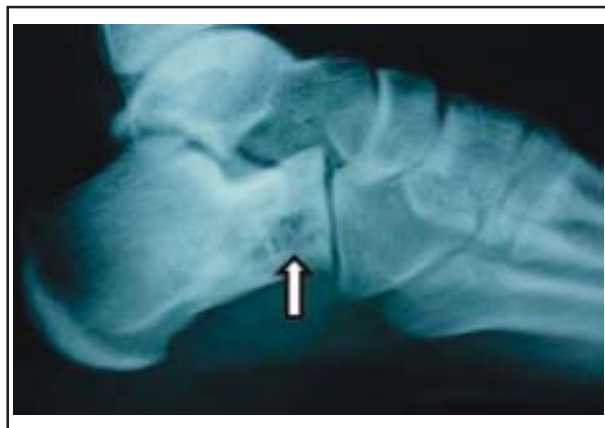

Figure-1: Lateral radiograph of left calcaneus showing findings of osteomyelitic.

common problem of general practitioners and emergency physicians.¹ In a retrospective series of 200 cases in which foreign body was detected in the hand, Anderson reported that the foreign body was overlooked in 1/3 of the cases by the physician who initially attended the patient.⁵

Wooden foreign bodies embedded in the bone or soft tissue lead to chronic irritation and secondary infections. They cause osteolytic and/or osteoblastic changes in the bone. Unfortunately, this condition causes confusion.⁶ Radiolucent foreign bodies should be considered in the differential diagnosis of lytic lesions of the bone even if the patient does not have a history of injury.³

An overlooked or forgotten foreign body may cause abscess, tenosynovitis, draining sinus and osteomyelitis.^{1,3} Unremoved foreign bodies serve as a nidus for microorganisms; thus, healing of foreign body-related osteomyelitis is not possible without removing the foreign body. A history of foreign body should be investigated in orthopaedic infections unresponsive to treatment.^{2,6} Removal of foreign bodies is an invasive, expensive surgical intervention requiring experience.⁷

Preoperative detection of the location of the foreign body using imaging methods is important. A mistake in localization prolongs the operation time and causes wider soft tissue damage.⁸ Detection of wooden foreign bodies embedded in the extremity using imaging methods is difficult. They usually do not display findings on X-ray imaging and are overlooked easily. While CT, MRI and US (ultrasound) are usually utilized for detection of foreign bodies in soft tissue, CT and MRI are utilized for detection of foreign bodies in the bone.^{1,9} No pathological findings were found on US in our case. Hence, the

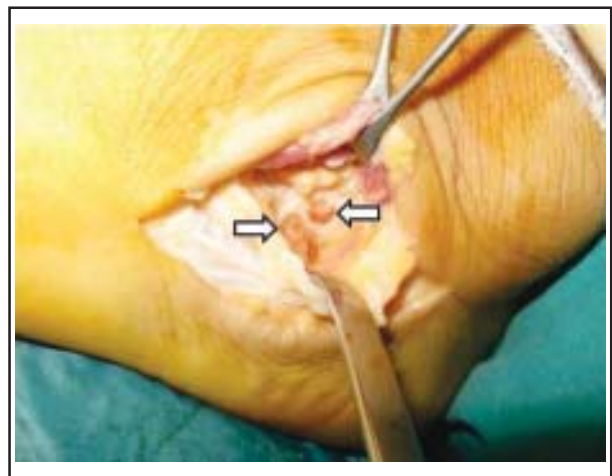


Figure-2: Intraoperative photograph of two pieces of wooden foreign body embedded in the calcaneus.

wooden foreign body was considered to have been embedded in the bone. Non-specific findings are frequently observed in the evaluation of wooden foreign bodies with MRI.⁶ The foreign body displays an air appearance if it is dry. The level of visualization decreases in one week as the wooden body absorbs the neighbouring blood and extracellular fluid.¹⁰ Furthermore, the extent of the decrease in visualization differs according to wood types. Hence, the success of imaging methods decreases in delayed cases. Imaging methods are also insufficient when the foreign bodies are of small size, and in the absence of abscess and collections.^{6,11} In our case, the reason for the inability to detect the foreign body on MRI was considered to be the small size.

In conclusion, foreign bodies retained in the tissue should be investigated in penetrating injuries presenting to the emergency department, especially in skin cuts related to glass and wooden bodies. Radiolucent foreign bodies should be taken into consideration in acutely injured patients in which a foreign body cannot be detected on plain radiographies and US should be performed as the initial test. The procedure should not be terminated after removal of the foreign body, and the presence of a second, even a third foreign body should be investigated. Losing no time, an immediate surgical exploration should be performed in patients with an anamnesis of foreign body injury and infection irrespective to long lasting treatment, in whom the foreign body could not be detected with imaging methods.

REFERENCES

1. Pai VS. Wooden foreign bodies in the hand. *NZ Med J* 1997;110(1045):215.
2. Vidyadhara S, Rao SK. Thorn prick osteomyelitis of the foot in barefoot walkers: A report of four cases *J Orthopaedic Surg* 2006;14(2):222-224.
3. McGuckin JF Jr, Akhtar N, Ho VT, Smergel EM, Kubacki EJ, Villafana T. CT and MR evaluation of a wooden foreign body in an in vitro model of the orbit. *AJNR Am J Neuroradiol* 1996;17(1):129-133.
4. Stevens MA, De Coster TA, Renwick SE. Cactus thorn embedded in the cartilaginous proximal tibia. *West J Med* 1995;162(1):57-59.
5. Anderson M, Newmeyer WL, Kilgore ES. Diagnosis and treatment of retained foreign bodies in the hand. *Am J Surg* 1982;144:63-65.
6. Peterson JJ, Bancroft LW, Kransdorf MJ. Wooden foreign bodies: imaging appearance. *AJR Am J Roentgenol* 2002;178(3):557-562.
7. Callegari L, Leonardi A, Bini A, Sabato C, Nicotera P, Spano' E, Mariani D, Genovese EA, Fugazzola C. Ultrasound-guided removal of foreign bodies: personal experience. *Eur Radiol* 2009;19(5):1273-1279.
8. Kobs JK, Hansen AR, Keefe B. A retained wooden foreign body in the foot detected by ultrasonography. A case report. *J Bone Joint Surg Am* 1992;74(2):296-298.
9. Siegel IM. Identification of Non-Metallic Foreign Bodies in Soft Tissue: Eikenella corrodens Metatarsal Osteomyelitis Due to a Retained Toothpick. *J Bone Joint Surg Am* 1992;74:1408-1410.
10. Ginsberg LE, Williams DW, Mathew VP. CT in penetrating craniocervical injury by wooden foreign bodies: Reminder of a pitfall. *AJNR* 1993;14:892-895.
11. Orlinksky M, Knittel P, Feit T, Chan L, Mandavia D. The comparative accuracy of radiolucent foreign body detection using ultrasonography. *Am J Emerg Med* 2000;18(4):401-403.