

Neonate with congenital transverse deficiency of hand

Hafiza Fizzah Riaz¹, Sajid Malik²

ABSTRACT

Congenital transverse limb deficiency is a rare anomaly which manifests itself as aplasia/hypoplasia of the distal structures of limb in transverse axis while the proximal limb remains relatively normal. There is a wide phenotypic variability; the minor type appears as unilateral reduction through the autopod/digits while the extreme forms are characterized by tetramelic transverse imputations through the stylopod. Here, we present the clinical detail and follow up of a male neonate with unilateral transverse deficiency of right hand. The fingers were completely omitted in the affected autopod while a single bead-like nubbin was attached at the radial aspect of the truncated hand. Palm was also reduced and tri-radius was not recognizable. In the roentgenographs, humerus appeared hypoplastic, radius and ulna were dysplastic and proximally fused, and all the digital elements were absent. There was no involvement of any other organ system. Transverse limb defects put a tremendous impact on the affected subject and their families as complete recovery and management through surgery is not possible. Hence, the measures to reduce the prevalence and etiology to these defects are strongly recommended.

KEY WORDS: Limb deficiency, Transverse limb anomaly, Congenital hand amputations, Finger reduction, Pakistani subject.

Pak J Med Sci October - December 2011 Vol. 27 No. 5 1177-1180

How to cite this article:

Riaz HF, Malik S. Neonate with congenital transverse deficiency of hand. Pak J Med Sci 2011;27(5):1177-1180

INTRODUCTION

Congenital transverse limb deficiency is a rare anomaly with an estimated prevalence of 2–7 in 10,000 live births.^{1,2} It manifests itself as aplasia/hypoplasia of distal structures of limbs in transverse axis while the proximal limb remains relatively normal.³ The minor phenotype appears as unilat-

eral reduction through the autopod/digits while the extreme forms are characterized by tetramelic transverse amputation through the stylopod (i.e., humerus/femur). The reduction through the hand may involve only certain phalanges (aphalangia), only the digits (adactyly) or full hand (acheiria), all are considered as various degrees of the same deformity. The malformation may be unilateral or bilateral and may affect upper and/or lower limbs. Most of the cases reported in medical literature are sporadic and isolated. Both genetic and environmental causes have been suggested for transverse deficiencies. Here, we present case report and follow up of a sporadic male neonate with unilateral transverse deficiency of right hand without any other malformation.

CASE REPORT

The subject, a male neonate, originates from a remote village of Southern Punjab. His parents were

1. Hafiza Fizzah Riaz,

2. Sajid Malik,

1, 2: Human Genetics Program, Department of Animal Sciences, Quaid-i-Azam University Islamabad, 45320 Islamabad, Pakistan.

Correspondence:

Dr. Sajid Malik,
Assistant Professor, Human Genetics Program,
Department of Animal Sciences,
Quaid-i-Azam University Islamabad,
45320-Islamabad.
E-mail: malik@qau.edu.pk

* Received for Publication: July 6, 2011

* Accepted: October 7, 2011

first cousins (inbreeding coefficient, $F = 0.0625$), and he was the youngest of five phenotypically unaffected elder sisters. His prenatal events and delivery had been unremarkable. At the time of his birth, his mother and father aged 19 and 24 years, respectively. The subject was initially examined at the age of one month, and was subsequently followed-up for the next six months in order to monitor developmental landmarks. Detailed clinical and radiological data, physical and anthropometric measurements, and photographs were obtained, accordingly.

The subject had short right arm with the hand devoid of fingers, and there was congenital transverse amputation through the palm (Fig. 1A, 1B). Fingers were completely absent while a bead-like nubbin, remnant of a digit, was evident at the radial aspect of truncated hand (Fig. 1A, 1B). The nubbin was attached through a skin-stalk and harbored a deformed convex nail. Additionally, a rudimentary 5th finger was observed to be attached at the posterior-distal aspect of truncated palm (Fig.1B). Palmer dermatoglyphics were grossly absent and the tri-radius was not recognizable. The affected arm had normal extension and flexion at the wrist and elbow joints. Roentgenographic examination of the affected arm revealed a short humerus with hypoplasia of distal end (Fig.1C, Table-I). In the middle arm, radius and ulna were dysplastic and closely aligned. The ulna was particularly short in size (Fig.1C). Additionally, the proximal ends of radius and ulna were fused while the distal ends were hypoplastic. Carpals/metacarpals were represented by at least one immature chondrogenic island (Fig.1C).

Left arm appeared unaffected and it demonstrated normal developmental parameters (Fig.1D). In the roentgenographs, two carpals and five metacarpals were evident and all finger had normal phalanges (Fig.1E). There were no other symptoms of orofacial, skeletal or neurological systems. He observed normal growth landmarks (Table-I). There was no family history of limb defects or any other malformation of hereditary nature.

DISCUSSION

The status of transverse limb anomalies remains unexplored in Pakistan. There is no data available on the prevalence, epidemiology and genetics of these defects. It is also not clear how much economic, psychological and genetic burden on the Pakistani society is rendered by the congenital limb deficiencies/transverse anomalies. Therefore, this research area requires further investigations at epi-

Table-I: Physical, anthropometric and roentgenographic measurements of subject.

<i>Anthropometric parameters</i>	<i>Measurements in cm</i>	
Height	63.0	
Sitting height	38.0	
Head circumference	44.5	
Leg length	12.5	
<i>Clinical and radiological measurements</i>	<i>Left arm</i>	<i>Right arm*</i>
Humerus-distal head (circumference)	2.4	1.9
Middle arm (Zeugopod)	9.5	7.0
Radius	7.0	7.0
Radius-distal head	1.3	0.9
Ulna	8.0	6.8
Ulna-distal head	0.9	0.6
Radius/Ulna space	0.8	0.5
Hand (Autopod)	8.0	2.0
Palm	5.0	3.7
Carpal island 1	0.5 x 0.5	Absent
Carpal island 2	0.5 x 0.5	Absent
Metacarpal I	1.3	Absent
Metacarpal II	2.0	Absent
Metacarpal III	1.9	Absent
Metacarpal IV	1.2	Absent
Metacarpal V	1.5	Absent
Digit I	2.3	Absent
Digit II	3.2	Absent
Digit III	3.7	Absent
Digit IV	3.4	Absent
Digit V	3.0	Absent

* affected limb. All measurements were taken at the age of six months.

demiological, clinical and molecular genetics levels.

Most of the transverse limb defects reported in the medical literature were unilateral. For instance, Reed⁴ reported radiological features of 15 cases of transverse deficiency of forearm, all being unilateral. Likewise, all the 27 cases of transverse deficiencies recruited by Ogino and Saitou⁵ were unilateral.

Transverse amputations mostly occur as isolated entities and no gene/locus is yet known for these isolated types. The anomaly in our subject is also isolated type and unilateral and its etiology remains unknown. For this case, we can exclude constriction rings syndrome which is usually accompanied by circumferential constriction ring around the affected appendage and fusion of distal parts ranging from mild to gross acrosyndactyly. A few genetic factors however, have been discovered for syndromic types of transverse limb deficiencies. For instance, acheiropodia (OMIM 200500)⁶ shows bilateral tetramelic amputations in which humerus/

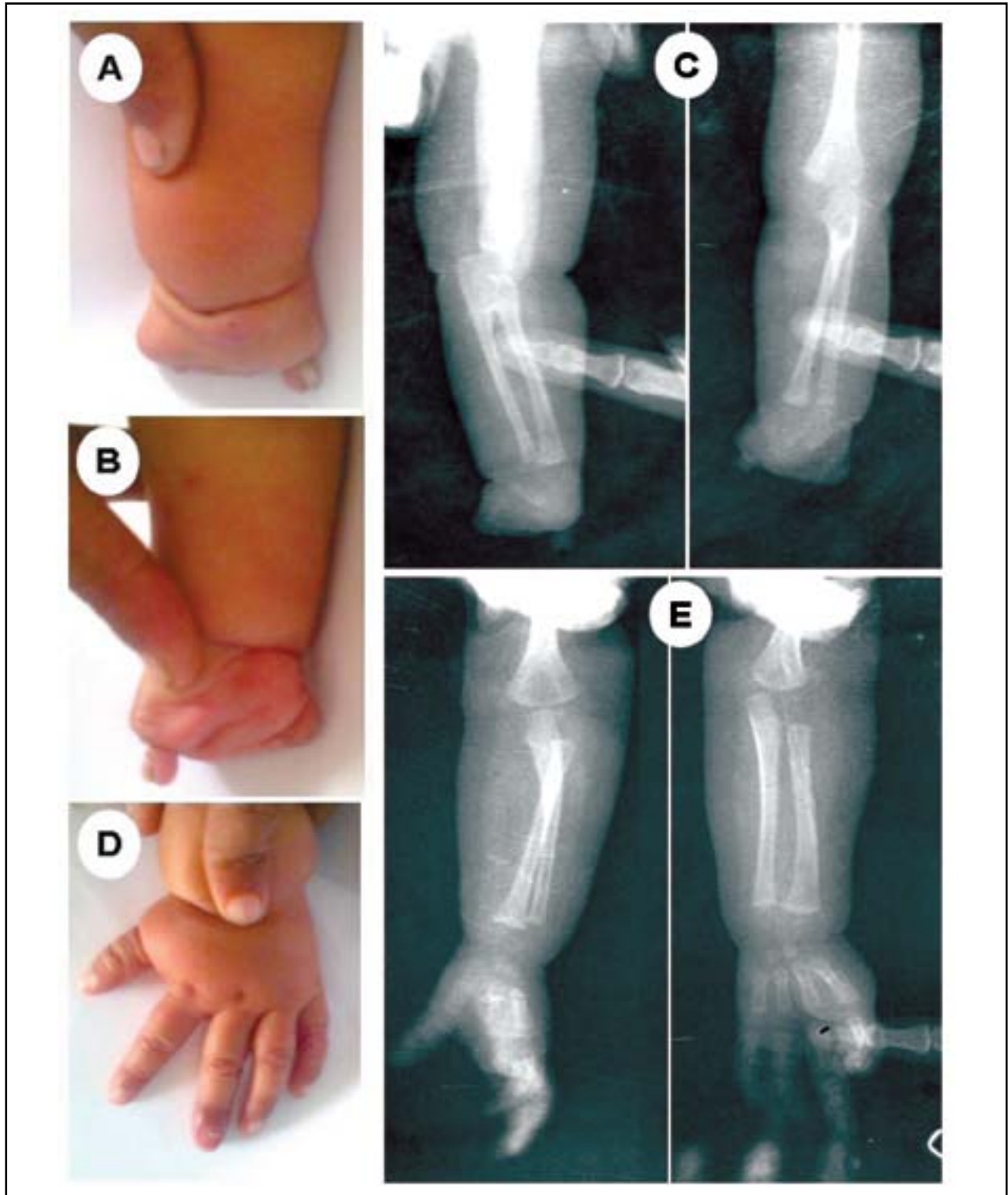


Figure-1: Phenotype in the subject.

- (A): Dorsal aspect of right hand depicting transverse amputation and a single nubbin.
 (B): Ventral aspect of right hand showing rudimentary 5th finger juxtaposed with the truncated palm.
 (C): Roentgenographs of right arm.
 (D, E): Photograph and roentgenograph of the left normal arm. The middle finger had a newly emerging nail after an injury.

femur are also involved. It segregates as an autosomal dominant entity and the mutations in *LMBR1* gene on chromosome 7q36 have been implicated for this anomaly. Charcot-Marie-tooth disease (OMIM 600882)⁶ also depicts transverse limb defects in addition to symptoms of peripheral sensory neuropathy and ulcero-mutilating neuropathy. This anomaly has many distinct genetic variants and several underlying loci/genes have been worked out. Recently, Adams-Oliver syndrome (OMIM 100300)⁶ which also shows transverse limb defects, has been mapped to chromosome 3q and the mutations in *ARHGAP31* gene have been discovered.⁷

Additionally, there are other syndromic malformations which show variants of transverse anomalies like microgastria-limb reduction defects (OMIM 156810), cleidocranial dysplasia with micrognathia (OMIM 216340)⁶, aphalangia with syndactyly and duplication of metatarsal IV (OMIM 600384)⁶, the genetic basis of which are not yet known. The genes known to be expressed in the most distal extremity of the developing limb, the apical ectodermal ridge (i.e., *FGF8*, *FGF4*, *FGF9*, *FGF17*, *MSX1*, *MSX2*, *DLX5*, *DLX6*, *BMP2*, *BMP4*, *BMP7*), could be good candidates for terminal transverse limb anomalies.⁸

Transverse defects and absence anomalies of limb put a tremendous impact on the affected subjects and their families. In several cases particularly in severe forms, complete recovery and management thought surgical methods is not possible. Hence, the measures to reduce the prevalence and etiology of limb defects have been strongly recommended. For instance, in a genetic epidemiological approach, Cleves et al⁹ have studied the association between the occurrence of nonsyndromic limb reduction defects and the polymorphisms in the genes involved in the folate and methionine pathway. Their results suggested the possibility that initiating folic acid

supplementation prior to pregnancy may reduce the risk of having a limb reduction defect-related pregnancy. Further studies are required to identify effective intervention measures for congenital limb defects and transverse anomalies.

ACKNOWLEDGEMENTS

We acknowledge the participation of subject and his family in this study. This study was supported by the Higher Education Commission Islamabad, and Pakistan Science Foundation.

REFERENCES

1. McGuirk CK, Westgate MN, Holmes LB. Limb deficiencies in newborn infants. *Pediatrics* 2001;108(4):E64.
2. Wynne-Davies R, Lamb DW. Congenital upper limb anomalies: an etiologic grouping of clinical, genetic and epidemiological data from 382 patients with "absence" defects, constriction bands, polydactyly and syndactyly. *J Hand Surg* 1985;10:958-964.
3. Temtamy SA, McKusick VA. The genetics of hand malformations. New York: Alan R. Liss. 1978.
4. Reed MH. Radiologic features of congenital transverse deficiencies of the forearm. *Can Assoc Radial J* 1991;42(5):345-348.
5. Ogino T, Saitou Y. Congenital constriction band syndrome & transverse deficiency. *J Hand Surg (Br)* 1987;12(3):343-348.
6. OMIM. Online Mendelian Inheritance in Man. <http://www.ncbi.nlm.nih.gov/omim>
7. Southgate L, Machado RD, Snape KM, Primeau M, Dafou D, Ruddy DM, et al. Gain-of-function mutations of *ARHGAP31*, a *Cdc42/Rac1* GTPase regulator, cause syndromic cutis aplasia and limb anomalies. *Am J Hum Genet* 2011;88(5):574-585.
8. Niswander L. Pattern formation: old models out on a limb. *Nat Rev Genet* 2003;4:133-143.
9. Cleves MA, Hobbs CA, Zhao W, Krakowiak PA, MacLeod SL. National Birth Defects Prevention Study. Association between selected folate pathway polymorphisms and non-syndromic limb reduction defects: a case-parental analysis. *Paediatr Perinat Epidemiol* 2011;25(2):124-134.