

## Long QT syndrome in a patient with complete heart block causing torsades de pointes

Ali Raza Rajani<sup>1</sup>, Kosar Hussain<sup>2</sup>, Ghazi A. Radaideh<sup>3</sup>, Sanjeev K. Agarwal<sup>4</sup>

### ABSTRACT

Long QT syndrome (LQTS) is an uncommon cardiac disorder of repolarisation leading to prolonged QT interval and T wave abnormalities in the ECG, thus predisposing to *Torsades de Pointes* (TdP). This condition could either be congenital or acquired. Patients with this clinical syndrome may present with syncope or even sudden cardiac death. We are reporting a case of a 59-year-old female patient who presented to our hospital with a history of dizziness on exertion. Her ECG showed complete heart block and prolonged QTc interval, which precipitated to TdP. Her condition resolved uneventfully after initiation of permanent pacing.

**KEY WORDS:** Long QT syndrome; *Torsades de pointes*; Complete heart block; VT.

Pak J Med Sci April - June 2012 Vol. 28 No. 3 512-515

### How to cite this article:

Raza Rajani A, Hussain K, Radaideh GA, Agarwal SK. Long QT syndrome in a patient with complete heart block causing torsades de pointes. Pak J Med Sci 2012;28(3):512-515

### INTRODUCTION

Long QT syndrome (LQTS) is a cardiac disorder that causes an increased risk of syncope and even sudden cardiac death, due to ventricular tachyarrhythmias. A study by Nemeč et al has reported the prevalence of LQTS to be 1 in 5,000 persons.<sup>1</sup> LQTS is caused by various mutations in the genes encoding for cardiac ion channel subunits, leading to abnormalities in repolarisation. The mutations can involve either the Na channels or K channels and results in increased influx of Na<sup>+</sup> or decrease K<sup>+</sup> efflux, both of which may predispose to *Torsades de Pointes* (TdP).

1. Ali Raza Rajani, FCPS, MRCP,
  2. Kosar Hussain, MBCh,
  3. Ghazi A. Radaideh, Jordanian Board, FRCP,
  4. Sanjeev K. Agarwal, MD, DM (Cardiology), FACC,
- 1,3,4: Department of Cardiology,  
1-4: Rashid Hospital, Dubai,  
United Arab Emirate (UAE).

#### Correspondence:

Dr. Ali Raza Rajani,  
Department of Cardiology, Rashid Hospital,  
Dubai, United Arab Emirate (UAE).  
E-mail: rajani\_ali@hotmail.com

\* Received for Publication: December 26, 2011

\* Accepted: March 10, 2012

### CASE REPORT

A 59-year-old female was brought to our hospital from the airport as she developed dizziness with exertion, without any loss of consciousness. She denied any history of palpitation, chest pain or shortness of breath. She was not a diabetic, hypertensive or smoker. She denied any recent use of antibiotics or anti-histaminic agents. She was implanted with a permanent pacemaker at the age of 43 years for reasons unknown to the patient. There was no family history of syncope, sudden death or any cardiac disease. On examination, her blood pressure was 130/70mmHg and pulse 36/min regular. Cardiovascular and respiratory examinations were unremarkable.

The blood investigation showed hemoglobin of 12.7gm/dL, sodium 142mmol/L, potassium 3.5mmol/L, calcium 9.1mg/dL, magnesium 2.42mg/dL, urea 18mg/dL and creatinine 0.9mg/dL. Cardiac enzymes were normal and troponin was negative. Fig.1 shows the ECG at the time of admission. It showed complete heart block with a ventricular rate of 36/min with broad and inverted T-waves. No pacemaker spikes were seen, thus indicating possible end of life of pacemaker generator.

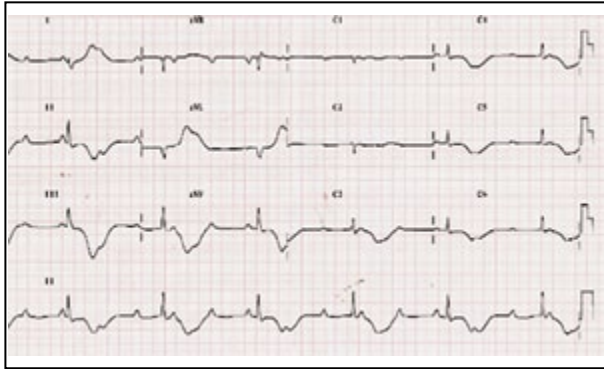


Fig.1: ECG at the time of admission showed complete heart block.

Her chest x-ray showed a pacemaker device in right infraclavicular area with a single ventricular lead. Grossly there was no evidence of fracture or damage of the lead. On echocardiography, the cardiac chambers and valves appeared normal. The left ventricular functions were fair with EF 55%, mild MR and mild TR and RVSP 41mmHg.

Patient was admitted in CCU for insertion of temporary pace-maker. While in CCU she developed runs of TdP and she was feeling dizzy during these episodes (Fig.2). Amiodarone and magnesium sulfate were given but failed to abort the VT episodes. Electrolyte levels, including calcium and magnesium levels were within normal range. On reassessment of the initial ECG, it was revealed that the patient had prolonged QT interval. The QTc by Fridericia's cube root formula and Bazett's square root formula were 675ms and 620ms respectively. Once the temporary pacemaker was inserted and the ventricle was paced at 60/min, the TdP did not recur and the patient showed marked clinical improvement. Next day, her old pacemaker generator was changed. The lead was checked and adequate parameters were obtained. The QTc duration of the paced rhythm had shortened to 440ms (by both Bazett's and Fridericia's formulae). She was

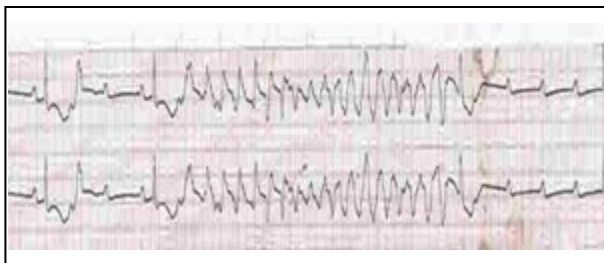


Fig.2: Patient's rhythm strip showing Torsades de pointes.

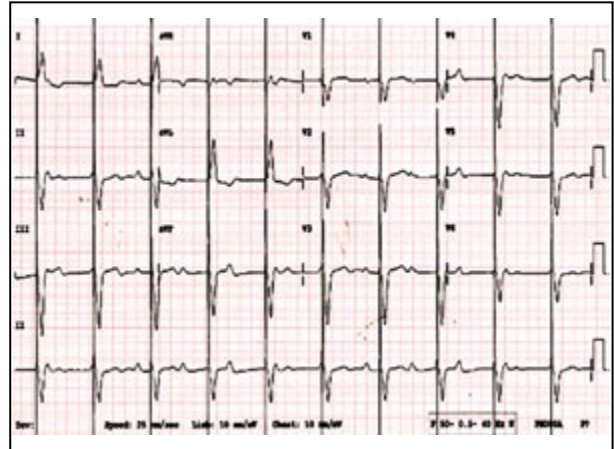


Fig.3: ECG after changing pacemaker generator.

closely-monitored for three days during which she remained hemodynamically stable and there was no recurrence of any ventricular tachyarrhythmia. Fig.3 shows the ECG at discharge.

### DISCUSSION

Causes of QT prolongation can be divided into congenital and acquired causes. The first variant of congenital LQTS was initially described by Jervell and Lange-Nielsen in 1957 in a Norwegian family which manifested by sensorineural deafness, recurrent syncope during exercise and sudden death. Later in 1963-1964 Romano and Ward described a similar condition with normal hearing. It was later recognized that there were different subtypes of congenital LQTS based on the type of genetic mutation involved.

A study conducted by Priori et al on 647 patients with LQTS found the incidence of cardiac arrest or death to be 13% among patients who did not receive treatment.<sup>2</sup> This is because patients with LQTS are at increased risk of developing ventricular tachyarrhythmias, such as TdP.

The diagnostic criteria for LQTS were re-updated by Schwartz in 2006.<sup>3</sup> Table-I lists the various ECG, clinical and familial factors that are included in the clinical diagnostic assessment score. The score ranges from 0 to 9 points, thus describing the probability of LQTS. The score is divided into three categories:  $\leq 1$  point = low probability;  $> 1$  to 3.0 points = intermediate probability; and  $\geq 3.5$  points = high probability.

Our patient had initially presented with pre-syncope and her ECG revealed complete heart block, prolonged QTc interval with broad and deep T wave inversion. Later she developed

recurrent episodes of TdP. Our patient's Schwartz diagnostic criteria score was 5.5 and this indicates high probability of LQTS. Her old pacemaker generator had become non-functional. This caused her to develop complete heart block that unmasked the prolonged QT interval, which ultimately precipitated to polymorphic VT. After changing the pacemaker generator and maintenance of heart rate at 70bpm, the patient improved clinically and the TdP resolved.

Bradycardia with prolonged QT interval is known to be one of the major factors predisposing to TdP. A retrospective Spanish study by Diaz-Castro et al. found out that the presence of prolonged QTc interval conferred an increased risk for the occurrence of ventricular fibrillation or TdP in patients with acute symptomatic bradycardia.<sup>4</sup>

On the other hand, there is increasing interest in understanding the relation between AV block and risk for TdP. A study by Kurita et al investigated fourteen patients with complete atrioventricular block. They demonstrated that there was significant prolongation of the QT and QTc intervals among patients with complete heart block who develop TdP as compared to those who do not develop TdP: 753 +/- 57.5 vs 635 +/- 78.4 ms ( $p < 0.01$ ) and 585 +/- 44.8 vs 476 +/- 58.3 ms ( $p < 0.01$ ).<sup>5</sup>

Subiah et al suggested that patients with TdP in the setting of atrioventricular block represent a phenotypic manifestation of latent congenital long QT syndrome. They seem to represent underlying genetic predisposition to reduced repolarization reserve.<sup>6</sup> A similar conclusion was made by Oka et al. that TdP that is triggered by atrioventricular block can be a manifestation of clinical phenotypes of long QT syndrome, and that some patients with AV block-induced TdP share a genetic background with those with congenital LQTS.<sup>7</sup>

In our literature review, we found few case reports that were similar to our case. Indik has also reported a similar case study of a 65-year-old female who developed dizziness and found to have complete heart block with QT interval of 800ms and markedly abnormal T wave. She was demonstrated to have episodes of TdP on holter monitoring. After insertion of the pacemaker, the T- waves normalized and QT interval shortened.<sup>8</sup> Similarly Gladman et al reported about two children who developed TdP as a result of long QT interval after acquiring complete heart block. Both the children did well after pacemaker insertion.<sup>9</sup>

Table-I: Schwartz's updated LQTS diagnostic criteria (2006).

<i>Electrocardiographic findings<sup>a</sup></i>	
QTc <sup>b</sup>	
>480 ms	3
460-470 ms	2
450-459 (male) ms	1
Torsades de pointes <sup>c</sup>	2
T-wave alternans	1
Notched T wave in 3 leads	1
Low heart rate for age <sup>d</sup>	0.5
<i>Clinical history</i>	
Syncope <sup>e</sup>	
With stress	2
Without stress	1
Congenital deafness	0.5
<i>Family history<sup>e</sup></i>	
A. Family members with definite LQTS	1
B. Unexplained sudden cardiac death below age 30 amongst immediate family members	0.5

<sup>a</sup>In the absence of medications or disorders known to affect these electrocardiographic features.

<sup>b</sup>QTc calculated by Bazett's formula where  $QTc = QT / \sqrt{RR}$ .

<sup>c</sup>Mutually exclusive.

<sup>d</sup>Resting heart rate below the 2nd percentile for age.

<sup>e</sup>The same family member cannot be counted in A and B.

Similar cases were reported by Maor et al in two elderly female patients who presented with syncope and dyspnea. Their ECGs showed prolonged QT interval, AV block and TdP. The TdP disappeared after pacemaker insertion.<sup>10</sup>

## CONCLUSION

The LQTS is an under-diagnosed entity. Proper history and vigilant ECG reading will help in discovery of new cases. Prompt recognition of this disorder can reduce morbidity and mortality. TdP with LQTS has many causes and an important cause is the bradyarrhythmias. Thus in our case the TdP was precipitated by complete heart block when her pacemaker's generator reached end of life. In this case, after replacing the pacemaker generator, QTc interval shortened and this suppressed occurrence of TdP.

## REFERENCES

1. Nemeč J, Hejlik JB, Shen W, Ackerman MJ. Catecholamine-Induced T-Wave Lability in Congenital Long QT Syndrome: A Novel Phenomenon Associated With Syncope and Cardiac Arrest. *Mayo Clinic Proceedings*. 2003;78(1):40-50.
2. Priori SG, Schwartz PJ, Napolitano C, Bloise R, Ronchetti E, Grillo M, et al. Risk Stratification in the Long-QT Syndrome. *N Engl J Med*. 2003;348(19):1866-1874.
3. Schwartz PJ. The congenital long QT syndromes from genotype to phenotype: clinical implications. *J Intern Med*. 2006;259(1):39-47.
4. Díaz-Castro O, Puchol A, Almendral J, Torrecilla EG, Arenal A, Martínez-Selles M. Predictors of in-hospital ventricular fibrillation or torsades de pointes in patients with acute symptomatic bradycardia. *J Electrocardiol*. 2004;37(1):55-60.
5. Kurita T, Ohe T, Marui N, Aihara N, Takaki H, Kamakura S, et al. Bradycardia-induced abnormal QT prolongation in patients with complete atrioventricular block with torsades de pointes. *Am J Cardiol*. 1992;69(6):628-633.
6. Subbiah RN, Gula LJ, Leong-Sit P, Skanes AC, Yee R, Klein GJ, et al. Torsades de pointes during complete atrioventricular block: Genetic factors and electrocardiogram correlates. *Canadian J Cardiology*. 2010;26(4):208-212.
7. Oka Y, Itoh H, Sakaguchi T, Miyamoto A, Kawamura M, Matsuura H, et al. Atrioventricular block-induced torsades de pointes with clinical and molecular backgrounds similar to congenital long QT syndrome. *Circ J*. 2010;74(12):2562-2571.
8. Indik JH. Not Just Slow: Double Trouble. *Am J Med* 2008;121(1):19-20.
9. Gladman G, Davis AM, Fogelman R, Hamilton RM, Gow RM. Torsade de pointes, acquired complete heart block and inappropriately long QT in childhood. *Can J Cardiol*. 1996;12(7):683-685.
10. Maor N, Weiss D, Lorber A. Torsade de pointes complicating atrioventricular block: report of two cases. *Int J Cardiol*. 1987;14(2):235-238.