

DISTALLY BASED SURAL ARTERY FLAP: A workhorse to cover the soft tissue defects of lower 1/3 Tibia and Foot

Mehtab A. Pirwani¹, Saeed Samo², Yunis H. Soomro³

ABSTRACT

Objective: To present our experience of soft tissue cover of lower one third of tibia and foot, treated by an Orthopaedic Surgeon without any special training and reliability of this flap.

Patients and Methods: Eleven patients, ten males and one female, with soft tissue defect of lower one third tibia and foot requiring soft tissue cover were treated from March 1999 to February 2004. The flap was outlined at the posterior aspect of junction of upper and middle 1/3 leg. The pivot point of the pedicle was at least 5cm i.e., 3 fingers' breadth above the lateral malleolus to allow anastomosis with the peroneal artery. Skin incision was started along the line in which the fascial pedicle would be taken. The subdermal layer was dissected to expose the sural nerve, accompanying superficial sural vessels and short saphenous vein. The subcutaneous fascial pedicle was elevated, with a width of 2cm to include the nerve and these vessels. At the proximal margin of the flap, the nerve and the vessels were ligated and severed. The skin island was elevated with the deep fascia. The donor site defect was closed directly when the flap was less than 3cm wide. A larger donor site defect along with the pedicle was covered with a split thickness skin graft.

Results: All flaps except one survived. Most flaps showed slight venous congestion which cleared in a few days. There was no loss of split skin graft.

Conclusion: Distally based Sural artery flap remains the choice for reconstruction of soft tissue defects of lower 1/3 tibia and foot. The dissection is easy, quicker and can be done by an Orthopaedic surgeon without any special training.

KEY WORDS: Soft tissue defects, Distally based Sural artery flap, Lower 1/3 tibia & foot.

Pak J Med Sci January - March 2007 Vol. 23 No. 1 103-107

INTRODUCTION

Soft tissue defects of lower 1/3 tibia and dorsum of foot presents a challenging problem. The patients are being treated by Plastic Surgeons.¹ Most open fractures of lower 1/3 of tibia are associated with soft tissue defects,

because tibia is subcutaneous bone with almost no muscles around its lower 1/3 with tight skin and poor circulation. Heel is another problem site because of weight bearing properties, hence it needs a full thickness skin cover. Different forms of soft tissue cover are available e.g., muscle flap, fascial flaps, septocutaneous flaps, axial flaps and free flaps with their own indications and disadvantages.

The distally based Sural artery flap, first described as a distally based neuro cutaneous flap by Masquelet et al,² is skin island flap supplied by the vascular axis of sural nerve. He reported, using colored latex injection studies in 1992, the blood supply to the skin from the arteries accompanying the nerves and described the concept of neuro cutaneous island flap. The objective of this paper was to present

1. Dr. Mehtab A. Pirwani,

2. Dr. Saeed Samo,

3. Dr. Yunis H. Soomro,

1-3: Department Of Orthopaedics,
Unit-II, Dow University of Health Sciences
& Civil Hospital,
Karachi - Pakistan.

Correspondence:

Dr. Mehtab A. Pirwani,

E-mail: mehtabpirwani@cyber.net.pk

* Received for Publication: April 28, 2006

* Revision Received: May 9, 2006

* Revision Accepted: June 26, 2006

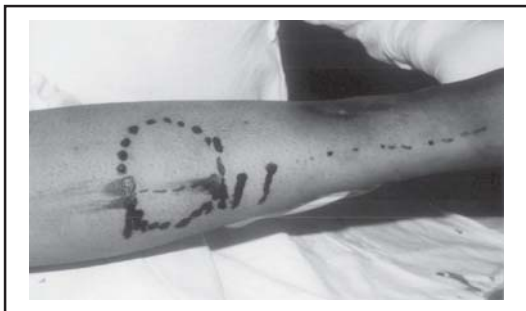

Fig-I: The flap outlined at the posterior aspect of junction of upper and middle 1/3 leg

our experience of soft tissue cover of lower 1/3 of tibia and foot treated by an Orthopedic surgeon without any special training, and also the reliability of this flap.

PATIENTS AND METHODS

Eleven patients, ten males and one female, with soft tissue defect of lower 1/3 tibia and foot requiring soft tissue cover were treated from March 1999 to February 2004. The patient's age ranged from 18 to 40 Years (mean 23 Years). Two of the wounds were over the dorsum of foot, six were on the lower 1/3 of tibia and three were on the posterior heel. Patient with Diabetes Mellitus, Tuberculosis, I.H.D and cigarette smokers were excluded.

The sural neurovascular flap,³⁻⁶ is a fasciocutaneous flap that is raised along the course of the sural nerve. The nerve emerges between the two heads of gastrocnemius muscle in the middle of the popliteal fossa and

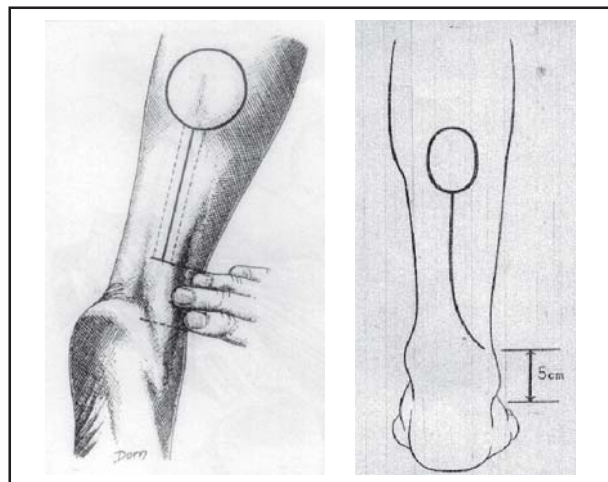


Fig-III: The pivot point of the pedicle at least 5cm i.e., 3 fingers' breadth above the lateral malleolus

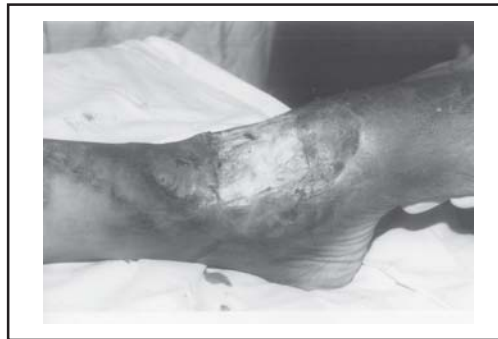

Fig-II: Prepared pattern of the recipient defect

travel to the lateral aspect of the heel between the lateral malleolus and the anterior margin of the Achilles tendon. Its blood supply depends on a constant sural artery that accompanies the nerve along its very proximal course. Distally it depends on perforators coming from the peroneal artery. The most distal set of perforators leave the peroneal artery at almost 5 cm i.e., three fingers' breadth proximal to the tip of the lateral malleolus.

With the patient in a lateral position or prone position, the flap is outlined at the posterior aspect of junction of upper and middle 1/3 leg Fig-I. According to a previously prepared pattern of the recipient defect. (Fig-II) The pivotal point of the pedicle must be at least 5cm i.e., 3 fingers' breadth above the lateral malleolus to allow anastomosis with the peroneal artery³⁻⁶ (Fig-III).

Skin incision is started along the line in which the fascial pedicle will be taken. The subdermal layer is dissected to expose the sural nerve, accompanying superficial sural vessels and short saphenous vein (Fig-IV).

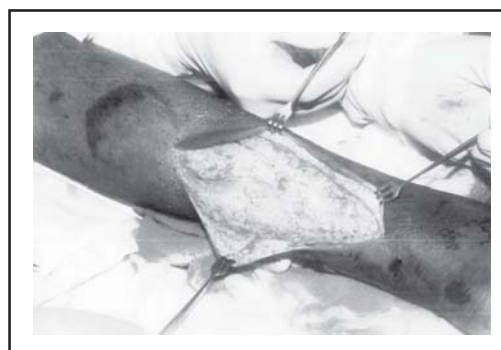


Fig-IV: Subdermal layer dissected to expose the sural nerve, accompanying superficial sural vessels and short saphenous vein

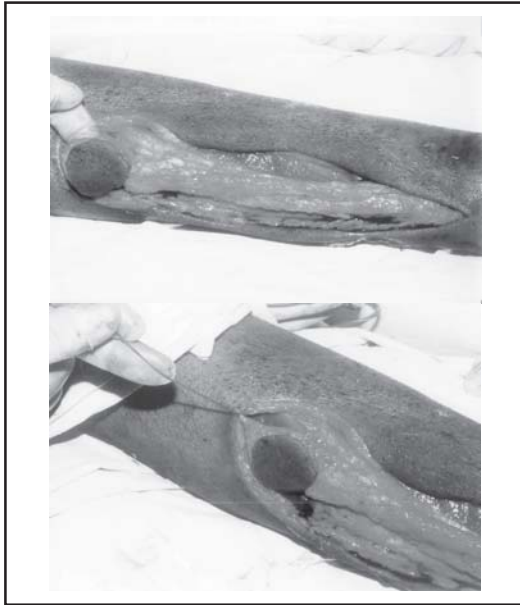


Fig-V: Superficial Sural nerve identified

The subcutaneous fascial pedicle is elevated, with a width of 2cm to include the nerve and these vessels. At the proximal margin of the flap, the nerve and the vessels are ligated and severed. (Fig-V) The skin island is elevated with the deep fascia. (Fig-VI) The donor site defect can be closed directly when the flap is less than 3cm wide. A larger donor site defect along with the pedicle must be covered with a split thickness skin graft. (Fig-VII)

RESULTS

The mechanism of injury was road traffic accident in seven patients with open fracture tibia and foot, spoke wheel injury in one patient, exposed plate in lower 1/3 due to wound dehiscence after operative treatment of fracture in one patient, exposed Tendo Achilles in two patients.




Fig-VI: The skin island elevated with the deep fascia

All flaps except one survived. Most flaps showed slight venous congestion which cleared within a few days. There was no loss of split skin graft and no complaints related to the sacrifice of the sural nerve. Paresthesia on the lateral border of the foot was not a problem and disappeared within two months.

DISCUSSION

Soft tissue defects of lower 1/3 tibia and foot used to be enigma of Orthopaedic and even Plastic and reconstructive surgeon.⁷ Trauma due to road traffic accidents or wound dehiscence due to operative treatment account for most of the cases. Various techniques have been developed for the reconstruction of these defects. Split skin graft remains the best option to cover superficial defects over dorsum of foot due to its faster take and early neurotization.

Fasciocutaneous flaps first introduced by Ponten in 1981,⁸ are in use for the reconstruction of soft tissue defects of lower 1/3 leg and foot. Reversed island flap e.g., peroneal artery flap, anterior tibial artery flap and posterior tibial artery flap can be transferred to the ankle or foot. However it needs sacrifice of a major artery which constitutes a potentially serious disadvantage. Masquelet et al² in 1992 first

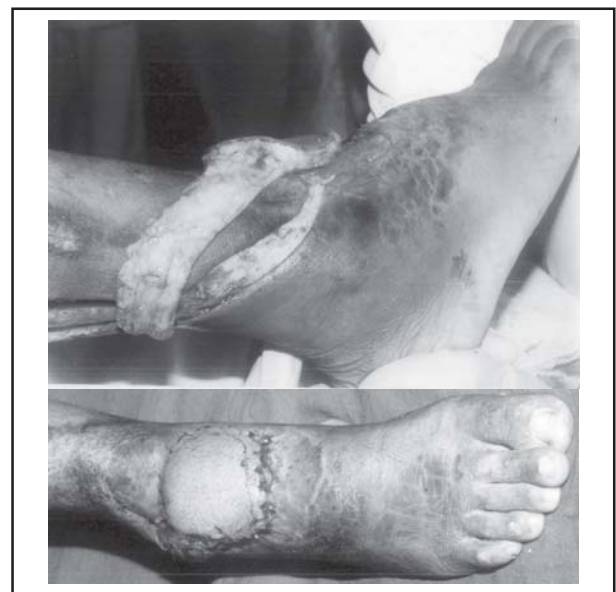

Fig-VII: Defect covered with flap

described distally based sural artery flap. The distally based superficial sural artery flap is vascularized by a median superficial artery with reverse flow as this artery has septocutaneous perforators from peroneal artery.

Additionally, the sural nerve has an intrinsic arterial system. These systems anastomose freely in the suprafascial plexus; combination of these systems perfuses the distally based superficial sural artery flap. The advantages of the flaps are that relatively large size flap can be harvested with little donor site deformity. Dissection is easy, blood loss is minimal & preservation of the major vascular structure of the lower limbs is possible. It also avoids the need for more sophisticated equipment and expertise. This flap has a wide arc of rotation on its pedicle at approximately 5cm superior to the lateral malleolus.

Jeng et al.⁹ used this technique to cover exposed Achilles tendons and soft tissue defects of the ankle and the heel. Of the 22 patients described, 20 had complete success with two minor complications that were treated uneventfully. Huisinga et al¹⁰ used this flap on 15 patients for soft tissue coverage in the lower leg, malleolar, and heel regions. Twelve flaps survived, two partially survived, and one flap failed due to persistent infection. Jeng et al¹¹ reported their experience with the use of the distally-based sural artery flap for salvage of the distal foot. In seven out of eight patients, the flaps survived completely and only one patient had a partial necrosis of the flap.

Coskunfirat et al¹² performed 11 reverse neurofasciocutaneous flaps for coverage of soft tissue defects in the lower extremities. Six flaps were saphenous and five were sural; all survived completely. Bocchi et al¹³ used a reverse sural flap in 14 patients to successfully cover larger defects of the leg and ankle and a reverse adipofascial sural flap in 11 patients to cover moderate-size wounds in heel areas. Ferreira et al¹⁴ reported that in 36 distally-based superficial sural artery flaps, only six partially necrosed and no major complications occurred.

In a larger study, Almeida et al¹⁵ performed a reverse flow island sural flap on 71 patients; 15 partially necrosed and three experienced total loss. Fraccalvieri et al¹⁶ described their experience with 18 distally-based superficial sural flaps. Only one superficial necrosis had to be surgically revised. Singh and Naasan¹⁷ used the reverse sural artery flap to treat acute open fractures of the lower leg associated with soft tissue loss. Two out of seven patients had a partial necrosis of the distal tip of the flap. We successfully elevated eleven distally based sural artery flaps, only one flap had necrosis. There was no major complication in rest of the cases although done by an Orthopaedic Surgeon.

Irrespective of aetiology, coverage of exposed soft tissue done in time is mandatory and essential for prevention of complications. Our clinical study recommends distally based sural artery flap as a good choice to cover soft tissue defects of lower 1/3 tibia and foot because the flap has numerous advantages. It is a one stage operation, which does not require microsurgical techniques. Elevation of the flap is easy and quick. The donor site has minimal morbidity as it can be closed primarily when small flap is raised and skin grafted when large flap is raised. The vascular supply to the arterial network of the sural area is constant and reliable, and there is no need to sacrifice any major artery and or sensory nerve. The pedicle is long, and the flap can be transferred around the lower 1/3 tibia and foot. Thus the distally based sural artery flap can be used as a good alternative to microsurgical reconstructions and can be done by an Orthopaedic Surgeon without any special training.

REFERENCES

1. Volgas DA, Scholl BM, Stannard JP. The Reverse-Flow Sural Artery Flap for Soft Tissue Injuries of the Lower Third of the Leg. OTA 2002 - Session III -Polytrauma.
2. Masquelet AC, Romana MC, Wolf G. Skin island flaps supplied by the vascular axis of the sensitive superficial nerves: anatomic study and clinical experience in the leg. *Plast Reconstr Surg* 1992;89:1115-21.

3. Nakajima H, Imanishi N, Fukuzumi S. Accompanying arteries of the lesser saphenous vein and sural nerve: anatomic study and its clinical applications. *Plast Reconstr Surg* 1999;103:104-20.
4. Le Fourn B, Caye N, Pannier M. Distally based sural fasciomuscular flap: Anatomic study and application for filling leg or foot defects. *Plast Reconstr Surg* 2001;107:67-72.
5. Yilmaz M, Karatas O, Barutcu A. The distally based superficial sural artery island flap: Clinical experiences and modifications. *Plast Reconstr Surg* 1998;102:2358-67.
6. Hasegawa M, Torii S, Katoh H, Esaki S. The distally based superficial sural artery flap. *Plast Reconstr Surg* 1994;93:1012-20.
7. Bhandari PS, Bath AS, Sadhotra LP. Management of Soft Tissue Defects of the Ankle and Foot. *MJAFI* 2005;61:253-5.
8. Ponten B: The fasciocutaneous flap. Its use in soft tissue defects of the lower leg. *Br J Plast Surg* 1981;34:215-20.
9. Jeng SF, Wei FC. Distally based sural island flap for foot and ankle reconstruction. *Plast Reconstr Surg* 1997;99:744-50.
10. Huisinga RL, Houpt P, Dijkstra R, Storm van L JB. The distally based sural artery flap. *Ann Plast Surg* 1998;41:58-65.
11. Jeng SF, Wei FC, Kuo YR. Salvage of the distal foot using the distally based sural island flap. *Ann Plast Surg* 1999;43:499-505.
12. Coskunfirat OK, Velidedeoglu HV, Sahin U, Demir Z. Reverse neurofasciocutaneous flaps for soft-tissue coverage of the lower leg. *Ann Plast Surg* 1999;43:14-20.
13. Bocchi A, Merelli S, Morellini A, Baldassarre S, Caleffi E, Papadia F. Reverse fasciosubcutaneous flap versus distally pedicled sural island flap: two elective methods for distal-third leg reconstruction. *Ann Plast Surg* 2000;45:284-91.
14. Ferreira AC, Reis J, Pinho C, Martins A, Amarante J. The distally based island superficial sural artery flap: clinical experience with 36 flaps. *Ann Plast Surg* 2001;46:308-13.
15. Almeida MF, Robero da Costa P, Okawa RY. Reverse flow island sural flap. *Plast Reconstr Surg* 2002;109:583-91.
16. Fraccalvieri M, Verna G, Dolcet M. The distally based superficial sural flap: our experience in reconstructing the lower leg and foot. *Ann Plast Surg* 2000;45:32-9.
17. Singh S, Naasan A. Use of distally based superficial sural island artery flaps in acute open fractures of the lower leg. *Ann Plast Surg* 2001;47:505-10.