

A RARE CASE OF HYPOMELANOSIS OF ITO

Sh. Shaafi¹, H. Herizchi²

ABSTRACT

Hypomelanosis of Ito (HI) is a syndrome with hypopigmented whorls of skin along the Blascho lines. The old name, Incontinentia pigmentosa achromia was probably used because HI appears to be the negative image of incontinentia pigmentosa. This disorder is inherited as an autosomal - dominant trait with variable penetrance and the implicated genes are 9q33 and q11-13, Xp11. Chromosomal mosaicism is believed to be the reason that hypomelanosis of Ito is so varied in phenotype. Hypopigmented skin lesions appear as whorls or streaks on any part of body and tend to progress onto uninvolved areas. The cutaneous lesion is often associated with developmental and neurological abnormalities. Pyramidal tract dysfunction, mental retardation and seizures are common neurological signs. Ophthalmologic disorders are also present.

KEYWORDS: Incontinentia pigmentosa achromians, Diagnostic criteria, Hypomelanosis Ito.

Pak J Med Sci January - March 2008 Vol. 24 No. 1 173-174

INTRODUCTION

Hypomelanosis of Ito (HI) is a syndrome with hypopigmented whorls of skin along the Blascho lines. Diagnosis is based on the characteristic hypomelanosis and international criteria of ITO. No pathognomonic laboratory test is available. Therapy is directed toward the associated complications, such as antiepileptic drugs for seizures. We report a rare case of this disorder in a 9-years old child with completely unilateral skin lesions.

CASE REPORT

A 9 year- old girl was admitted in our hospital for intractable seizures. She had history of secondary generalized tonic-clonic seizures from early childhood. The familial history

proved negative for genetic and heritable familial disorders. The neonatal period was uneventful. Her past medical history was characterized by seizures attacks from early childhood that was treated with Phenobarbital, carbamazepine and sodium valproate (with optimal doses). On admission the patient was awake and alert. She had minimal mental retardation and had subtle pyramidal tract dysfunction in her right limbs. The hypopigmented streaks and whorls were seen only in the right side of the body (cutaneous lesions were limited to the right side of the body and the left side was uninvolved (as her mother said these skin lesion have existed since infancy). Laboratory examination showed the following significant findings: routine and serologic tests were within normal limits. Ophthalmological examination showed no abnormalities except hypopigmentation and heterochromia of iris in the right side. In genetic consultation, autosomal dominant pattern of inheritance with 50% penetrance was reported. In the neuroimaging a hypointense lesion in the left parietooccipital lobes were reported (Fig-1). EEG showed a generalized slowness with epileptiform discharges lateralized to left leads (Fig-2). Her seizures were controlled with Depakine chrono and tegretol and for cutaneous lesion no specific treatment was needed.

1. Sh. Shaafi MD,
Assistant Professor of Neurology,
Department of Neurology, Razi Hospital,
2. H. Herizchi MD,
Assistant professor of Dermatology,
Department of Dermatology, Sina Hospital,
1-2: Tabriz University of Medical Science,
Tabriz - Iran.

Correspondence
Dr. Sh. Shaafi
E-mail: ShaafiS@tbzmed.ac.ir

- * Received for Publication: July 26, 2007
- * Revision Received: October 2, 2007
- * 2nd Revision Received: October 20, 2007
- * Final Revision Accepted: October 26, 2007

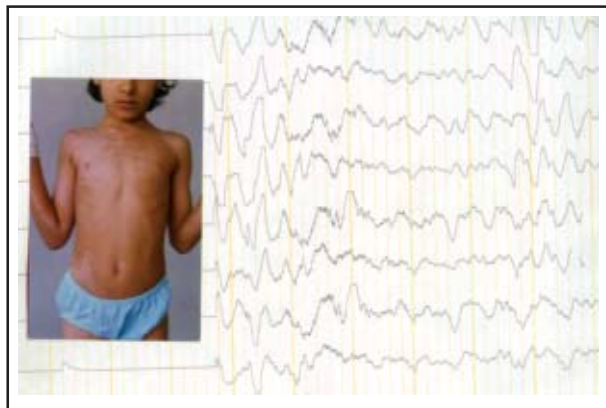


Figure-1

DISCUSSION

Neurocutaneous disorders are severe genetic disorders that involve both the skin and nervous system. The clinical spectrum ranges from frequent abortive forms to a severe potentially lethal condition with highly protean manifestation.¹ The old name, Incontinentia pigmentosa achromia was probably used because HI appears to be the negative image of incontinentia pigmentosa.² Hypomelanosis of Ito is a genetic disorder that is inherited as an autosomal-dominant trait with variable penetrance and the implicated certain genes are 9q33 and q11-13, Xp11.³ In 1992, Ruiz-Maldonado and associates established some diagnostic criteria for HI syndrome.⁴ Nonetheless, Ruiz-Maldonado et al's criteria link the diagnosis to the presence of systemic nondermatological (eg, CNS, skeletal) or chromosomal abnormalities. These criteria exclude patients with only dermatological manifestations. Patients with skin manifestations suggestive of HI with and without systemic alterations have been described in the same family, demonstrating that HI syndrome's systemic involvement can vary. Studies that do not include systemic manifestations as diagnostic criteria for HI reported that approximately 30-74% of patients with typical HI skin lesions do not have nondermatological pathology.⁵

In this syndrome the Hypopigmented skin lesion affect the skin in a characteristic manner and also the brain, eyes, musculoskeletal system. This syndrome is 1.5 -2.5 times more common in women and no racial preference is

reported. Hypopigmentation is present at birth and is not preceded by vesicular or verrucous lesion, Mental retardation and seizures are the most commonly associated conditions as reported in the medical literature and the neurologic abnormalities rate have been reported as high as 75-94%. But recently reported prevalence rate is 30-50%. Skin lesions include hypopigmented or with macules coalesce to form reticular patches cover more than 2 dermatome (often on the both sides of the body).⁶ The hypopigmented skin lesion are characterized by a decrease in the number of dopa-positive melanocytes and decreased pigmentation in the basal layer of the epidermis. Clinically and based on autonomic tests it can be differentiated from tuberous sclerosis. In tuberous sclerosis, the lesions are round, oval, or in the shape of an ash leaf and do not follow the lines of Blaschko.⁷ In addition Nevus depigmentosus is characterized by hypochromic lesions in streaks and whorls, which also follow the lines of Blaschko. The hypochromic lesions tend to be circumscribed and are present at birth, changing little thereafter. Systemic abnormalities are rare in nevus depigmentosus.⁸

In our reported patient the cutaneous lesions was limited to the right side of body with definite borders in the midline and associated systemic lesions were very limited and the presentation of the disorder was intractable seizure.

REFERENCES

1. Lewis P, Rowland. Neurocutaneous disorders, Merritt's Neurology 2000;596-9.
2. Ratz J, Gross N. Hypomelanosis of Ito, Emedicine 2007.
3. Koiffmann CP, deSouza DH, Diment A. Incontinentia pigmenti achromia (hypomelanosis of Ito): further evidence of localization at Xp11. Am J Med Genet 1993;46:529-33.
4. Meldonade RR. Hypomelanosis of Ito diagnostic criteria & report of the 41 patients. Pediatr Dermatol 1992;1-10.
5. Donat JF, Walsworth DM, Turk LL. Focal cerebral atrophy in incontinentia pigmenti achromia. Am J Dis Child 1980;134:709-10.
6. Aydingoz U, Midia M. Central nervous system involvement in incontinentia pigmenti: cranial MRI of two sblings, Neuroradiology 1998;40:364-6.
7. Jozwiak S, Schwartz RA, Janniger CK, Bielicka-Cymerman J. Usefulness of diagnostic criteria of tuberous sclerosis complex in pediatric patients. J Child Neurol 2000;15(10):652-9.
8. Jelinek JE, Bart RS, Schiff GM. Hypomelanosis of Ito (incontinentia pigmenti achromia). Arch Dermatol 1973;107:596-601.